

Low Level Laser Therapy of Sinusitis

M. Hacarova, ENT and Allergology, Dobnerova 26, Olomouc, CZ

**J. Hubacek, Faculty Hospital, ENT Clinic, I. P. Pavlova 6,
Olomouc, CZ**

ABSTRACT

The authors have been monitoring influence of a therapeutic laser (LLLT), wavelength 830 nm, output 40 - 120 mW, on treatment of acute sinusitis in 194 patients in group I (consisting of 20 patients with diagnosis of sinusitis maxillaris unilat., bilateralis - 145, frontalis unilat. - 2, pansinusitis - 24 patients). Control group II consisted of 241 patients with the same diagnosis, treated without the use of a laser. Energy density applied on children was 1.6 J/cm², 3 times every other day, on adults 2.5 J/cm², 5 times every other day on every affected sinus. Laser probe was applied externally on the skin of frontal wall of the sinus. 30 patients were treated with laser only, 91 patients were treated with laser and antihistaminics, 73 patients were treated with laser, antihistaminics and antibiotics. A significant analgetic effect of laser irradiation was noticed in all groups, the number of punctures decreased substantially in comparison with group II, presumably thanks to release of outlets of the sinus and improved drainage, the time of treatment decreased significantly. No complications were noticed.

Key words: acute sinusitis, LLLT, 830 nm

INTRODUCTION

Diagnosis sinusitis acuta is one of common types of diseases in out-patients medical practice, however it can cause patients severe problems. Majority of patients is mostly affraid of punctures which have become for our population the most feared ambulatory intervention. Some patients just cannot be convinced, and it was their negative attitude that made us consider thoroughly another way how to help them.

Laser irradiation has biostimulative, anti-inflammatory, and analgetic effects. Laser irradiation especially effects cellular membranes, membrane canaliculi and pumps, mitochondrias, cytoskeleton, nociceptors, fibroblasts, lymphocytes, polymorphonuclears and Langerhans cells. (1)

Irradiation of red lasers penetrates several milimeters into tissue, in infrared part of the spectrum the penetration goes up to several centimeters, usually 4 - 6 cm. This is a very advantageous fact for the treatment of sinusitis for laser irradiation can be applied externally. However, when applying a red laser it is necessary to introduce a lightguide in the sinus. This appears to be the main reason why laser treatment of sinusitis in clinical ENT practice has been lagging behind, since at first we had had for a long time only He-Ne lasers at our disposal.

INITIAL STUDY

We have initiated laser treatment of sinusitis with a therapeutic diode laser with wavelength 830 nm, the beam of which penetrates more than 4 cm into tissue. With 40 and 80 mW output power we used continuous mode as well as pulsed frequency 9.12 Hz.



Picture 1a: Sinusitis maxillaris - points of irradiation



Picture 1b: Sinusitis frontalis - points of irradiation

We irradiated the whole area above the sinuses, children three times with energy density 1.6 J/cm^2 every other day on each sinus, adults five times with energy density 2.5 J/cm^2 every other day on each sinus.

Group I consisted of 223 patients with diagnosis of sinusitis acuta with manifestations on maxillar sinuses, frontal sinuses and with pansinusitis.

We rejected 29 patients due for their clear evaluation was not possible due to the following reasons: condition after a surgery on sinuses, relapsing sinusitis on a rugged chronic operation field, or polyposis. With these patients x-ray pictures after the therapy could only hardly be evaluated.

Furthermore, other patients with immune system disorders and patients on whom LLLT had not been applied since the beginning of the treatment were rejected. Finally, one patient was rejected due to absence on his check up visit, too.

For comparative evaluation a retrospective monitoring of group II was used, where no laser was applied. Group II consisted of 241 patients, followed in our office between January 1 and December 31, 1997. Criteria for putting on group II was identical with those of group I, our surgery was not equipped with a laser at that time. The parameters followed in groups I and II (data in brackets) are presented in Table 1.

Table 1: Affection of individual sines

Affection of sinuses	unilateral	bilateral
----------------------	------------	-----------

Sinusitis maxillaris	20 (97)	145 (108)
Sinusitis frontalis	3 (3)	2 (2)
Pansinusitis	24 (31)	

In total 194 patients were evaluated in group I (69 children, 91 women, 34 men) with the age ranging from 4 to 70 years (Diagram 1), average age of adults was 43 years.

In group II 241 patients were evaluated (71 children, 112 women, 58 men), age ranging from 5 to 83 years (see Diagram 1), average age 38,5 years.

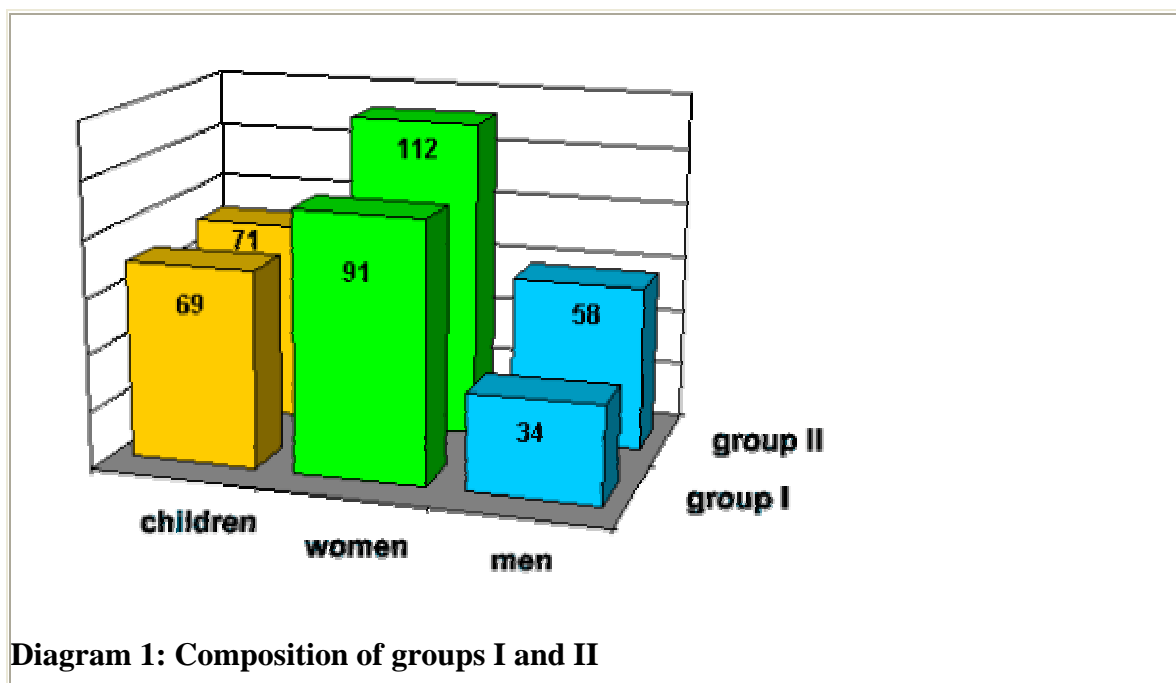


Diagram 1: Composition of groups I and II

Therapy was chosen in correspondence with the health condition of a patient and with regard to his/her clinical diagnosis, verified by a conventional x-ray picture of the sinuses. All our patients had taken standard nasal anaemic drops even before determination of the diagnosis sinusitis acuta.

On patients gathered in set A we applied laser (LLL) only. Set B was treated with laser + antihistaminics (loratadine or cetirizine), set C with laser + antihistaminics + antibiotics (usually amoxilines only, or enriched with potassium clavulanate or cefalosporines, in the event of preceding adverse reaction to ATB we used quite extraordinarily macrolides or clindamycine) in accordance with experience of ENT specialists of University of Irvine, California (7). (See Table 2).

Table 2: Group I

Sinusitis acuta	Set A - laser	Set B - laser + antihistaminics	Set C - laser + antihistaminics + ATB	Total	Patients with punctures
------------------------	----------------------	----------------------------------------	----------------------------------------------	--------------	--------------------------------

Catarrhal	26	56	21	103	1
Catarrhal + hyperplasia	3	14	17	34	0
Homogeneous veil	0	16	23	39	9
Liquid level	1	5	12	18	1
Total	30	91	73	194	11

In group II set A (laser) was excluded, other groups received the same medication as in group I. (See Table 3)

Table 3: Group II

Sinusitis acuta	Set A - laser	Set B - laser + antihistaminics	Set C - laser + antihistaminics + ATB	Total	Patients with punctures
Catarrhal	0	44	52	96	11
Catarrhal + hyperplasia	0	17	40	57	18
Homogeneous veil	0	9	42	51	23
Liquid level	0	6	31	37	21
Total	0	76	165	241	73

Average length of treatment was set from determination of diagnosis till clinical physiological ENT finding. Three patients from monitored group suffered from sinusitis maxillaris acuta twice in one year with 6 months interval, the group was monitored from December 1, 1998, till July 1, 2000, i.e. one and a half year in total.

Table 4: Average length of treatment in days - group I

Sinusitis acuta	Set A - laser	Set B - laser + antihistaminics	Set C - laser + antihistaminics + ATB
Catarrhal	6.3	7.9	7.6
Catarrhal + hyperplasia	9.5	8.5	9
Homogeneous veil	0	10.5	9.5
Liquid level	8	7.8	9.4

All patients were always monitored in the first day of treatment (once in the course of therapy) and upon the day of termination of therapy, all patients presented themselves for an ENT check up 6 months after the termination of therapy. Upon termination of treatment control x-rays of sinuses of patients with homogeneous veil or of patients with the findings

of liquid levels were taken, whilst control x-rays of patients with minor forms of sinusitis were taken only exceptionally. Average length of treatment in group II without LLLT application varied from 11.1 to 18.8 days.

Table 5: Average length of treatment in days - group II

Sinusitis acuta	Set A - laser	Set B - laser + antihistaminics	Set C - laser + antihistaminics + ATB
Catarrhal	0	11.1	12.4
Catarrhal + hyperplasia	0	12,3	13.6
Homogeneous veil	0	14.2	11.4
Liquid level	0	18.8	17.5

DISCUSSION

Only few papers on laser treatment of sinusitis can be found in literature. Kruchinina et al. (2) irradiated catarrhal and purulent maxillar sinusitis, both acute and chronic in 120 children inpatients in the age of 6 to 15 years, with He-Ne laser. A lightguide was inserted in the cavity by a drain, laser output power was 7mW/cm^2 , irradiation time 3 - 6 minutes daily. Consolidation came after 5 - 9 applications. Prior to therapy immunological examination showed decreased sIgA in the secret of the cavity, however values increased significantly after the treatment.

Plouzhnikov et al. (3) consider LLLT of acute and chronic sinusitis an important part of a comprehensive medicine. They irradiate with He-Ne laser 10mW/cm^2 by a lightguide inserted in the sinus through a puncture needle, 2 - 3 times on acute, and 5 - 9 times on chronic sinusitis. Energy density $2.1 - 8.4\text{ J/cm}^2$ has anti-inflammatory, anti-oedematous and analgesic effects.

Prazak (4) uses a semiconductor laser 830 nm. In case of an acute frontal sinusitis he applies 3 J/cm^2 on the area of foramen supraorbitale, and on another two frontal points of metopatron 1.5 J/cm^2 on each. In case of inflammation of gnathic sinus he irradiates the area of foramen infraorbitale by 3 J/cm^2 , and the areas of fossa canina a processus zygomaticus by 2 J/cm^2 . Simultaneously, he administers antipyretics, or antibiotics per os. LLLT decreases subjective complaints, especially headaches. He irradiates every day till consolidation, on chronic sinusitis 8 - 10 applications every other day.

Moustsen (5) with a group of colleagues from Aarhus Universitet conducted a double blind randomized study in 60 patients, on whom they applied laser irradiation of 30 mW, 830 nm, for 90 seconds, in three sessions on each sinus in 1 - 3 days interval. They found no statistically important difference between laser and placebo as far as pain feeling, disease duration, nor overall condition are concerned.

Simunovic (6) presents in the chapter "LLLT in ENT" treatment of sinusitis with a diode IR laser. He recommended energy density 2 - 4 J/cm² on mucous inflammations. Compared to other specialties, the chapter devoted to ENT is unusually brief - 3 pages of text only.

Therapy of sinusitis is focussed on suppressing infection, influencing unpleasant symptoms - especially pain, shortening duration of disease, preventing relapses and transformation into chronic phasis of the disease. These were our main concerns when monitoring the influence of laser irradiation on sinusitis.

1. We can quite unambiguously confirm a positive effect of laser on diminishing pain. In all monitored sets a relief of pressure and pain was noticed within 24 hours after the first irradiation in group I.
2. In therapy of sinusitis it is important to attain re-ventilation of the cavity and functional mucocilliar transportation of the secretion, depending on interaction of the mucus and function of cilia.

Significant decrease of number of patients, who had to undergo a puncture, bears witness to an influence of laser irradiation on release of outlets of sines and restoration of mucocilliar transportation. In gnathic and metopic sines the transportation is circular and it is directed by determined drainage paths, leading to natural sinusal outlets. The transportation ceases due to various reasons - toxins, medicaments, temperature, relation between liquid and viscose layers of the mucus, surfactants, or bilateral contact of the surface of the mucose, especially in the area of the outlets.

Most punctures, 8 of total 11 monitored patients with punctures in our group I, were performed in the cathegory with homogenous obscure of the sines treated with laser and antihistaminics (set B), whilst only one of 29 patients in the cathegory with homogenous obscure of the sinuses had to undergo punctures when treated with laser + antihistaminics + antibiotics (set C). Puncture empyema in set B was both blennoid and purulent. The number of patients with punctures in group II was also highest in the group with homogenous obscure - 23 patients (neither number of punctures, nor laterality was not taken into account). Laser irradiation is expected to bring a positive influence due to its anti-inflammatory and anti-oedematic effects especially in the area of the outlets. In the case of a homogenous obscure quantity, composition, and pressure of the mucus substantially impairs mucociliar transportation and, furthermore, the mucus prevents penetration of laser irradiation. Addition of antibiotics may contribute to a quicker elimination of inflammation.

3. Acute rhinogenous sinusitis is usually primarily viral, with secondary bacterial superinfection. According to our experience (8) laser irradiation has no bactericidal effect, however it causes reduction of cytopatogenous effect of herpes simplex virus, and the same effect can be presumed on other viruses. However, laser irradiation substantially stimulates non-specific as well as specific imune actions - it increases lysozoma in saliva, increases phagocytal activity, stimulates T and B lymphocytes and thus it through immunostimulation significantly contributes to healing processes.

4. All patients in group I were clinically checked up after six months. Patients with homogenous obscure of the sines or with levels were x-ray screened before and after

therapy. It was not necessary to hospitalize any patient, nor had any patient complications nor relapses within six months after therapy. No symptoms of chronic sinusitis were noticed.

Average duration of therapy varied between 6.3 to 10.5 days in group I (with LLLT), average duration of therapy in group II (without the use of laser) ranged from 11.1 to 18.8 days.

We are of the opinion that negative evaluation by Moustsen et al. (5) may be influenced by short application time.

CONCLUSIONS

LLLT irradiation is a benefit for treatment of acute sinusitis. External irradiation with a laser with 830 nm wavelength, enabling the beam to penetrate 4 - 6 cm deep is recommended. Irradiation with red light emitting lasers is also effective, but due to the need of application through a lightguide inserted into the cavity this method has been already discarded from clinical practice.

Laser irradiation works through its analgetic, anti-inflammatory and biostimulative effects on ease of pain, or even on its elimination, its also causes a quicker withdrawal of inflammation and oedema of the mucose and thus brings restoration of drainage of sines as well as normalisation of mucociliar function.

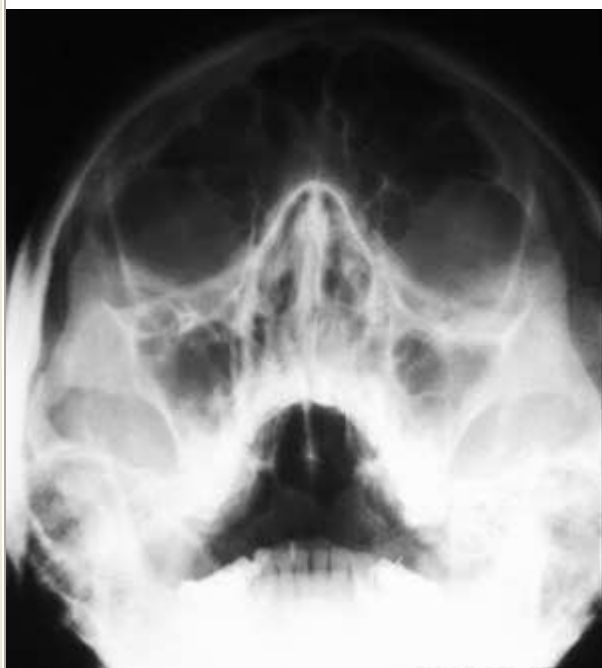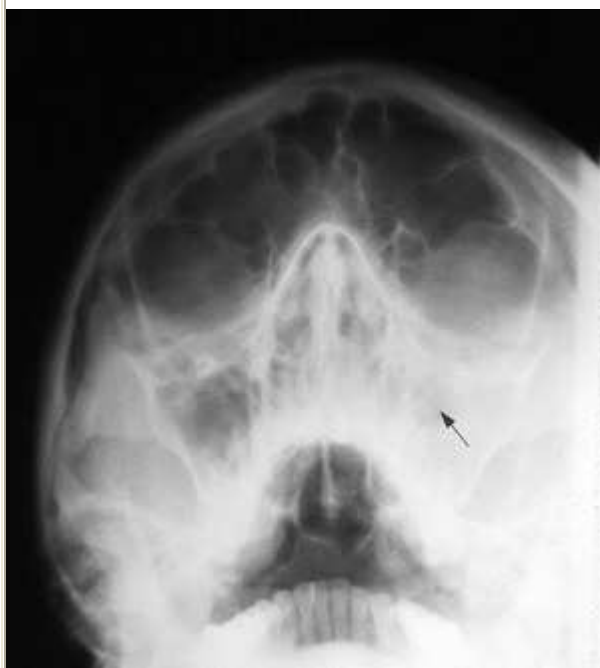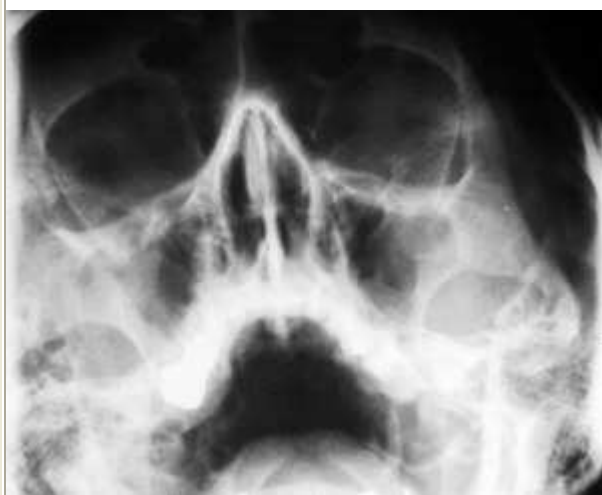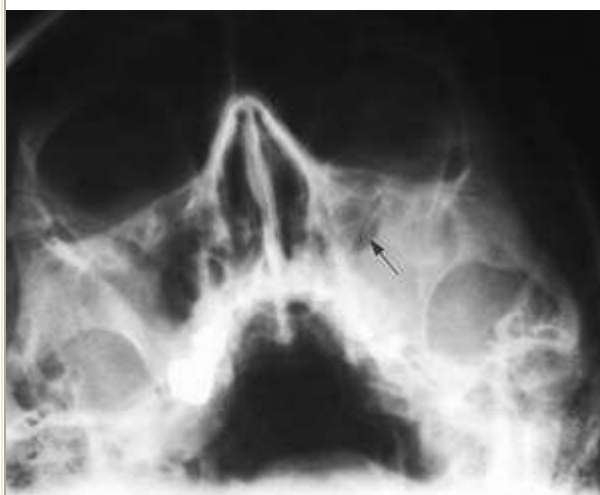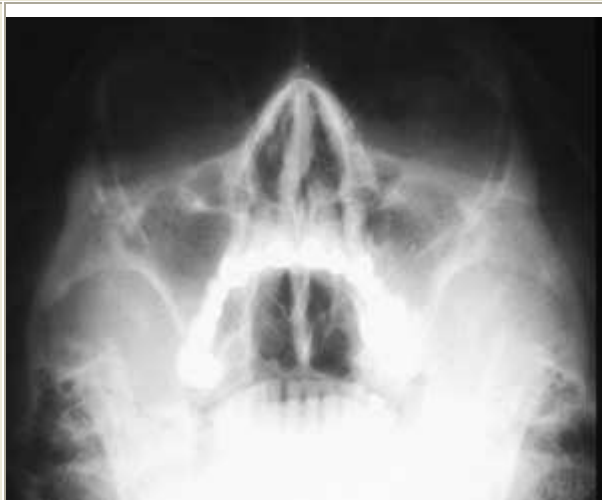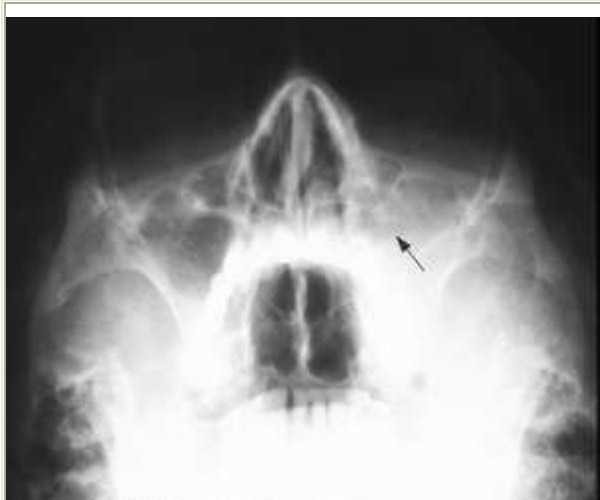Immunomodulative effect - improvement of both specific and non-specific immunities by stimulation of T and B lymphocytes, lysozyme and phagocytosis - is also significant. Stimulation of Langerhans cells of the mucose of sines is presumed, too.

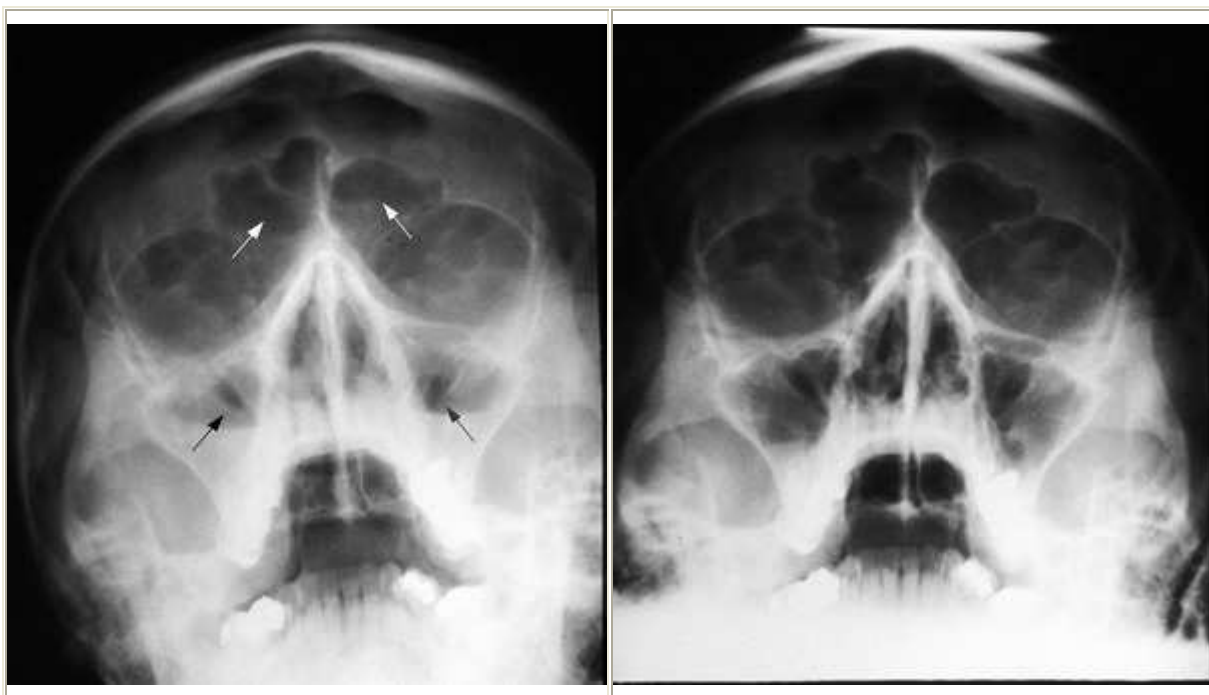Laser irradiation in treatment of sinusitis has no contraindications (with the exception of general contraindications, i.e. malignant tumors in the irradiation area, or epilepsy), and as a physiotherapy it can suitably complement therapy with antibiotics, mucolytics, and antihistaminics.

The use of laser with 830 nm wavelength appears to be the most beneficiary on diagnosis sinusitis acuta with liquid levels in paranasal sinuses, the treatment of which was cut down by 59 per cent in average, and on a group of patients with plain catarrhal obscure and decreased transparency (the most frequent) where duration of therapy was shortened by 39 per cent.

Total number of patients with punctures was cut down by about six times when using LLLT simultaneously.

Pictures 2a, 3a, 4a, 5a: X-ray of paranasal sinuses before LLLT (group I)	Pictures 2b, 3b, 4b, 5b: X-ray of paranasal sinuses after LLLT (group I)
------------------------------------------------------------------------------------------------	-----------------------------------------------------------------------------------------------





LITERATURE

1. Navratil, L., Hubacek, J.: Biologické účinky světelné energie, pages 53 - 93. In Moderní fototerapie a laseroterapie, Manus, Praha, 2000.
2. Kruchinina, I. L., Pekli, F. F., Rybalkin, S. V.: Vliv laseroterapie na místní syntézu imunoglobulinu třídy u dětí nemocných akutním i chronickým zánětem. Vest. Otorinolaryng., 1988, No. 2, pg. 19 - 21.
3. Plouzhnikov, M. S., Lopotko, A. I., Gagua, A. M.: Lasery v otorinolaryngologii. Kishinev, Shtiintsa, 1991, 157 s.
4. Prazak, P.: oral presentation 1996, 1999.
5. Moustsen, P.A., Vinter, N., Aas-Andersen, L., Kragstrup, J.: Laser Treatment of Sinusitis in General Practice Assessed by a Double-blind Controlled Study. Ugeskrift for Læger, 153 (32), 1991 Aug 5., pg. 2232 - 4.
6. Simunovic, Z.: Laser therapy in the diseases of ear, nose and throat. p. 381-383. In Laser in Medicine and Dentistry. Editor Zlatko Simunovic, Rijeka: Vitagraf 2000, 544 pgs.
7. Ahuja, G. S., Thompson, J.: What Role for Antibiotics in Otitis Media and Sinusitis?, Medicina po promoci, 1 (2000), Jan - Feb., pgs. 50 - 59.
8. Hubacek, J.: Neinvazivní laseroterapie v otorinolaryngologii, pgs. 130 - 150. I Moderní fototerapie a laseroterapie, Manus, Praha 2000.

Published in cooperation with <http://www.laserpartner.or>