



TECHNICAL NOTE

The use of vacuum-formed splints for temporary intermaxillary fixation in the management of unilateral condylar fractures

T. Lloyd,* C. Nightingale,† R. Edler‡

**Specialist Registrar, Oral and Maxillofacial Surgery; †Senior Registrar, Orthodontics, Queen Mary's University Hospital and Eastman Dental Hospital, London; ‡Consultant Orthodontist, Queen Mary's University Hospital, London, UK*

SUMMARY. We report a simple, effective method of managing displaced unilateral condylar fractures with occlusal disruption using vacuum-formed thermoplastic foil splints with bonded wire cleats. The cleats enable intermaxillary fixation in the form of orthodontic elastics to be used, which guide then maintain the occlusion in centric relation. A case is presented in which this technique was used successfully. © 2001 The British Association of Oral and Maxillofacial Surgeons

INTRODUCTION

Closed treatment has long been advocated for the treatment of fractures of the mandibular condyle^{1–3} and fractures in growing children are successfully treated in this way.⁴ There is a consensus of opinion regarding the management of condylar neck fractures in children.^{5,6} Open reduction and internal fixation may be indicated in bilateral injuries with loss of vertical ramus height.⁷ However, where the condyle is minimally displaced and the height of the ramus is normal, closed treatment is appropriate. This will normally consist of a delay while swelling and muscle spasm settle, followed by intermaxillary fixation with elastic guidance, not rigid fixation, for 1–6 weeks.⁴

Many techniques for the closed management of condylar fractures have been described. In the absence of occlusal disruption, no active treatment other than analgesics, soft diet and rest is required. However, if the patient is unable to achieve passive centric occlusion, more active treatment is indicated. Commonly this involves a short period of intermaxillary fixation with orthodontic elastic bands used to guide and maintain the mandible in centric occlusion.

There are various methods of attachment of the elastic bands: archbars, buttons or hooks, fixed to the dentition under local or general anaesthesia, silver cap splints or simply orthodontic brackets bonded to the teeth have all been used. However, they all have substantial disadvantages. Constructing customized archbars requires considerable

laboratory time, although a preformed variety is commercially available. Fixation of archbars to the teeth with stainless steel ligatures is awkward and uncomfortable under local anaesthetic, and, although these problems are eliminated under general anaesthesia, there are the risks that accompany this, in addition to the competition for theatre time. Silver cap splints are of historical interest only. Their cumbersome fabrication and difficulties associated with their removal have discouraged their use in favour of archbars. Placing individual orthodontic brackets in isolation and then applying elastic traction from these potentially causes disruption of the occlusion, as the bonded teeth are highly likely to extrude irreversibly under the influence of the elastic bands. However, to bond brackets to every tooth in a position to support a passive wire of sufficient rigidity to withstand elastic force is impossible without resorting to complicated wire bending.

The following method of application of temporary intermaxillary fixation overcomes these disadvantages.

CASE HISTORY

A 12-year-old girl was knocked down by a car and presented with painful facial swelling localized over the left condylar region, limited mouth-opening and mandibular deviation to the left. She was unable to close in centric relation. Other than a minor laceration to her chin, she had no additional injuries. Her medical history was

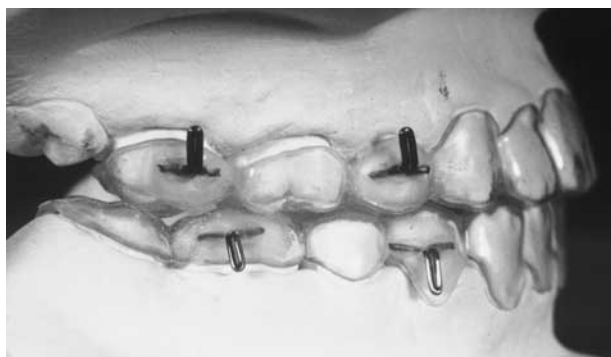


Fig. 1 Vacuum-formed splints 1 mm thick with bonded wire cleats ready for cementation.

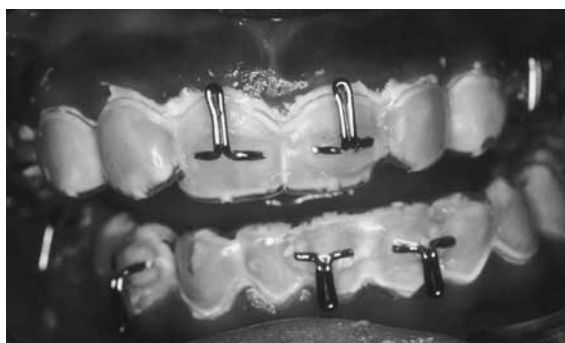

Fig. 2 Splints cemented with glass ionomer cement. The patient is unable to occlude in centric relation and the lower midline has deviated to the left.

clear. Radiographs (a dental pantomogram and postero-anterior skull views) confirmed the fracture of the left condyle, which was slightly displaced medially within the articular fossa.

Alginate impressions of both jaws were taken and stone working models poured. Vacuum-formed splints made from thermoplastic clear foil, 1 mm thick and 125 mm in diameter (Imprelon 'S') were constructed for both jaws. The material was heated to the manufacturer's specification for 50 s at a temperature of 220°C at a pressure of 6.2 bar using a Biostar vacuum-forming machine (Scheu-Dental, Postfach 7562 58613 Iserlohn, Germany). Six cleats made from 0.7-mm hard stainless steel wire were bonded with ordinary cold cure acrylic at regular intervals to each splint. The splints were trimmed with a tristar bur and several holes were drilled through the occlusal surfaces to allow for cement escape (Fig. 1). The splints were polished with pumice.

Using glass ionomer cement mixed to a fluid ('single cream') consistency, the splints were cemented intraorally and excess cement removed with a damp gauze swab (Fig. 2). Particular attention was paid to the occlusal

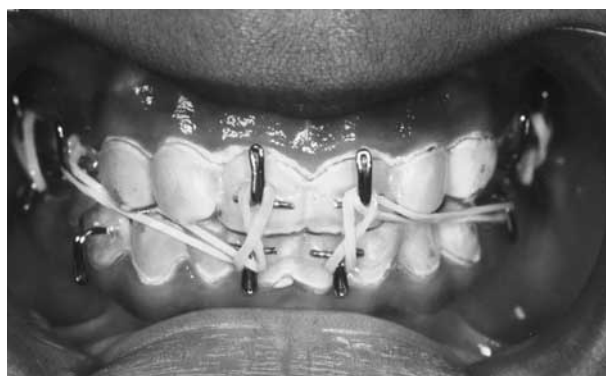

Fig. 3 Orthodontic elastics guide the patient into centric occlusion.

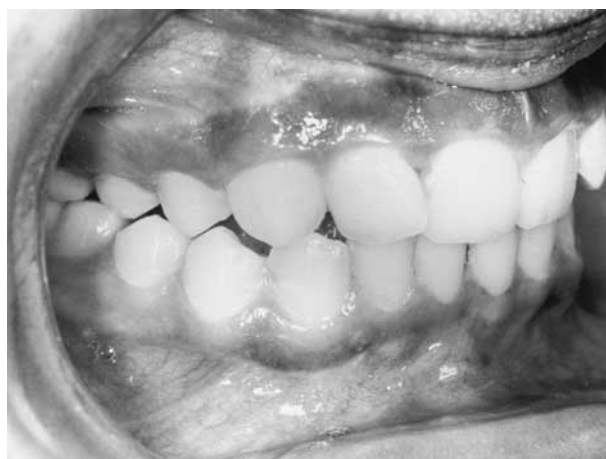

Fig. 4 Occlusion after treatment.

surfaces to ensure that the bite was not disturbed. Orthodontic elastics were positioned, with due consideration to their direction of pull, to guide the mandible back to centric occlusion (Fig. 3). The patient was reviewed at 3, 7 and 14 days later, and the elastic force was gradually reduced. The splints were removed at 4 weeks. When she was seen a week later, she was able to open her mouth fully, with some deviation to the left, and close in centric relation (Fig. 4).

Subsequently, a 42-year-old female with a unilateral fracture of the right condyle has been treated successfully by this method.

DISCUSSION

This technique proved to be successful. The patient was managed entirely in the out-patient unit and she experienced minimal discomfort. The splints were inexpensive and easy to make and the direction and magnitude of the intermaxillary fixation could be varied simply and quickly at every visit as required. Inevitably, the bite

was not completely closed due to the thickness of the splints and the cement. However, vacuum-formed splints are contoured closely over the occlusal surfaces and enable good interdigitation of the dentition. The bite was opened uniformly, there were no premature contacts and as the splint covered the entire occlusal surface, any overeruption of the dentition was impossible. Retention of the splints was achieved primarily by mechanical means because of the closely contoured properties of the plastic splints. In addition, further retention was ensured by the luting cement, glass ionomer, which has the ability to bond chemically to enamel.

Direct comparison with orthodontic bond strengths is not applicable as generally orthodontic bond strength studies have investigated bond strengths achieved between a stainless steel base, bonding agent and etched enamel. In this instance, bond strength is achieved between plastic, glass ionomer cement and unetched enamel. However, Wood *et al.* (1996) investigated the force required to deband first molar orthodontic bands from unetched third molars using glass ionomer, polycarboxylate and zinc phosphate cements.⁸ Glass ionomer cement provided the greatest strength, requiring a mean force of 1.23 megapascals (MPa) for debanding. It also has the advantage of leaching fluoride which minimizes decalcification. Removal of the splints and cement was straightforward.

CONCLUSION

The management of unilateral condylar fractures with occlusal disruption but without loss of vertical height is simple, using elastic intermaxillary fixation attached to vacuum-formed splints. Advantages over other methods of fixation include the fact that clinical work is completed entirely at the chairside without the need for general anaesthesia, the patient's discomfort is minimal, laboratory time is reduced, the materials are cheap and the magnitude and direction of intermaxillary fixation can be modified easily. This method of treatment should be

particularly useful in the management of mandibular condylar neck fractures in children.

ACKNOWLEDGEMENT

We would like to thank Mr Andrew Grosvenor, Senior Maxillofacial Technician, for constructing the splints.

REFERENCES

1. Members of the Chalmers J Lyons Club. Fractures of the mandibular condyle: a post treatment survey of 12 cases. *J Oral Surg* 1947; 5: 45–73.
2. MacLennan DW. Consideration of 180 cases of typical fractures of the mandibular condylar process. *Br J Plast Surg* 1952; 5: 122–128.
3. Blevins C, Gores RJ. Fractures of the mandibular condylar process: results of conservative treatment in 140 patients. *J Oral Surg* 1961; 19: 393–407.
4. Bos RRM, Ward Booth PR, de Bont LGM. Mandibular condyle fractures: a consensus. *Br J Oral Maxillofac Surg* 1999; 37: 87–89.
5. Kaban LB. Diagnosis and treatment of fractures of facial bones in children 1943–1993. *J Oral Maxillofac Surg* 1993; 51: 722–729.
6. Joos U, Kleinheinz J. Therapy of condylar neck fractures. *Int J Oral Maxillofac Surg* 1998; 27: 247–254.
7. Banks P. A pragmatic approach to the management of condylar fractures. *Int J Oral Maxillofac Surg* 1998; 27: 244–246.
8. Wood DP, Paleczny GJ, Johnson LN. The effect of sandblasting on the retention of orthodontic bands. *Angle Orthod* 1996; 66: 207–214.

The Authors

Timothy Lloyd MBBS, BDS, FRCS, FDSRCS

Specialist Registrar

Oral and Maxillofacial Surgery

Claire Nightingale MSc, BDS, FDSRCS, MOrthRCSEd

Senior Registrar, Orthodontics

Queen Mary's University Hospital and Eastman Dental Hospital
London, UK

Raymond Edler BDS, FDS, MOrth, RCSEd

Consultant Orthodontist

Queen Mary's University Hospital
London, UK

Correspondence and requests for offprints to: Mr T. Lloyd, MBBS, BDS, FRCS, FDSRCS, Specialist Registrar, Department of Oral and Maxillofacial Surgery, Eastman Dental Hospital, 256 Gray's Inn Road, London WC1X 8LD, UK. Tel: +44 (0)20 7915 1148; Fax: +44 (0)20 7915 1259

Accepted 21 March 2001