



# MAXILLOFACIAL REHABILITATION OF A 7-YEAR-OLD BOY WITH OSTEOSARCOMA OF THE MANDIBLE USING A FREE FIBULA FLAP AND IMPLANT-SUPPORTED PROSTHESIS: A CLINICAL REPORT

**Avinash S. Bidra, BDS, MDentSc,<sup>a</sup> Theresa M. Hofstede, DDS,<sup>b</sup> Roman J. Skoracki, MD,<sup>c</sup> and Rhonda F. Jacob, DDS, MS<sup>d</sup>**  
University of Texas Health Science Center, San Antonio, Tex;  
University of Texas, M.D. Anderson Cancer Center, Houston, Tex

This clinical report describes the multidisciplinary approach in the maxillofacial rehabilitation of a 7-year-old boy diagnosed with osteosarcoma of the mandible. Following surgical resection of the left half of the mandible from the angle to the parasymphiseal region, a free osseocutaneous flap from the fibula was used to successfully reconstruct the mandible. Dental implants were subsequently placed, and an implant-supported, removable mandibular resection prosthesis was fabricated. Prosthodontic planning and treatment considerations in a growing child with a reconstructed mandible are discussed. (*J Prosthet Dent* 2009;102:348-353)

Osteosarcoma (OS) is the most common malignant tumor of bones in children.<sup>1</sup> The incidence of osteosarcoma in the United States is 900 per year, with 400 instances occurring in persons under 20 years of age.<sup>2</sup> Most of them occur in the long bones. Surgery along with chemotherapy is the recommended treatment of choice and has demonstrated improvement in survival.<sup>3,4</sup> Primary OS of the head and neck is rare in pediatric patients, with only a few clinical reports and small clinical series reported in the English language literature.<sup>3,4</sup> Most instances occur in the second to third decades of life. They are more common in the mandible and have a predilection to women.<sup>5</sup>

Osteosarcomas are categorized in different grades (I-III) based on the severity, with grade III being the most severe type.<sup>4</sup> Metastasis is uncommon for OS of the jaws; however, the most common complication of OS of the jaws is local recurrence.<sup>5-7</sup> The few long-term prospective studies on this subject show a predictable survival after a 5-year period.<sup>4,8,9</sup> The primary treatment for OS of the jaws

is surgical excision and adjuvant chemotherapy.<sup>4-9</sup> The recommended surgical treatment results in large defects in the jaw which require a multidisciplinary approach for reconstruction and rehabilitation.

An understanding of growth of the maxilla and mandible is important for treatment planning in children.<sup>10</sup> The literature is clear that the growth of the mandible is completed earlier in girls than in boys.<sup>10-12</sup> Growth in a sagittal plane involves lengthening of the mandible by posterosuperior growth of the condyle and posterior growth of the ramus. The anterior part of the ramus shows resorption and the posterior part shows apposition. This may also be accompanied by rotation of the mandible.<sup>10,11</sup> Growth in a transverse plane involves enlargement of the mandible by the V principle where there is more enlargement posteriorly than anteriorly, as the mandibular symphyseal region shows little expansion after the suture is closed following the first year of birth.<sup>10,12</sup> Growth in a vertical plane involves growth due to forces of tooth eruption and alveolar bone deposition to establish

the occlusal plane.<sup>11,12</sup> The mandibular growth in all 3 planes has important clinical bearing. Sagittal growth analysis is important to understand occlusal relationships and facial esthetics. Transverse growth analysis is important in understanding occlusal relationships, compatibility with maxillary transverse growth, and facial esthetics. Vertical growth analysis is clinically important in occlusal vertical dimension issues and prosthetic space issues.

The fibula free flap technique for reconstruction of the mandible was first described by Hidalgo.<sup>13,14</sup> This technique has been reported to have advantages such as providing adequate length, reliable shape, low donor morbidity, and a distant location from the mandible to facilitate a multiteam approach.<sup>13</sup> It has been successfully documented in the literature for mandibular reconstruction, with a survival rate ranging from 95% to 100%.<sup>13,15-17</sup> However, the disadvantage of the fibula bone is the restricted height it can provide for mandibular reconstruction procedures. A cadaver study reported that the

<sup>a</sup>Assistant Professor, Department of Prosthodontics, University of Texas Health Science Center, San Antonio.

<sup>b</sup>Assistant Professor, Division of Maxillofacial Prosthodontics and Dental Oncology, University of Texas, M.D. Anderson Cancer Center.

<sup>c</sup>Assistant Professor, Department of Plastic Surgery, University of Texas, M.D. Anderson Cancer Center.

<sup>d</sup>Professor, Division of Maxillofacial Prosthodontics and Dental Oncology, University of Texas, M.D. Anderson Cancer Center.

average height of an adult fibula was anywhere from 10.6 to 11.1 mm.<sup>18</sup> No such data exist for children. The dimensions of the fibula are especially important for the placement of dental implants in these grafts. Fibula is a bicortical bone and is oval in cross-section; thus, in most instances, some flattening of the bone is required prior to implant placement, which may affect the length of the dental implant to be used. The success rate of dental implants in fibula has been well documented and ranges from 91.5% to 98.6%<sup>17,19-21</sup> Considerations for implant placement in children and related prosthodontic concerns have been well reported in the literature.<sup>11,12,22,23</sup> The purpose of this clinical report is to describe the multidisciplinary approach in the treatment of a 7-year-old boy with osteosarcoma of the mandible who underwent surgical resection followed by maxillofacial rehabilitation using dental implants.

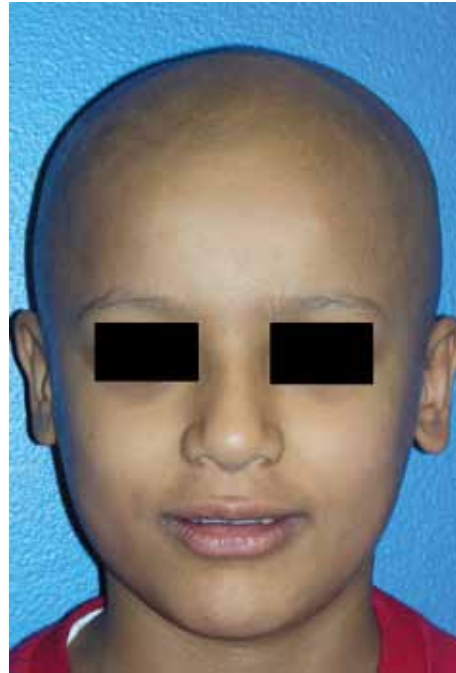## CLINICAL REPORT

A 7-year-old Arabic boy presented to his dentist with a rapidly progressing mass in his left mandible. Upon consultation with different medical specialists, he was diagnosed with grade III osteoblastic osteosarcoma. A metastatic examination including chest and bone scans was negative. At the time of presentation to M.D. Anderson Cancer Center, the patient was undergoing induction chemotherapy and was asymptomatic except for a partially numb lower lip and alopecia related to chemotherapy (Fig. 1). The patient did not receive radiation therapy. Clinically, there were no signs of tumor, but a computerized tomography (CT) scan showed obvious involvement of the left mandible. A comprehensive examination was done by a multidisciplinary team comprising a pediatric oncologist, radiologist, head and neck surgeon, plastic surgeon, and maxillofacial prosthodontist.

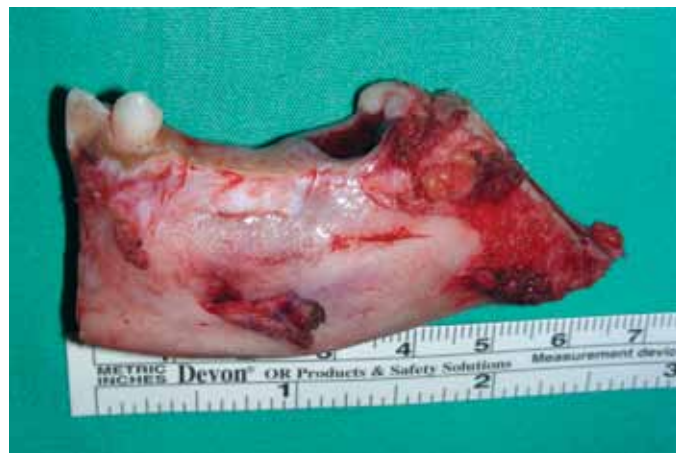Upon agreement between the patient's parents and the treatment

team with respect to the treatment plan, the surgery was performed under general anesthesia. Following tracheotomy, selective left neck dissection was performed. Prior to en bloc resection of the tumor, a titanium mandibular reconstruction plate (Angled Locking Reconstruction Plate; Synthes, West Chester, Pa) was contoured and adapted to the inferior border of the mandible by the maxillofacial prosthodontist. Thereafter, left mandibular resection was performed by the head and neck surgeon from the angle to the parasymphiseal region of the mandible (Fig. 2). The

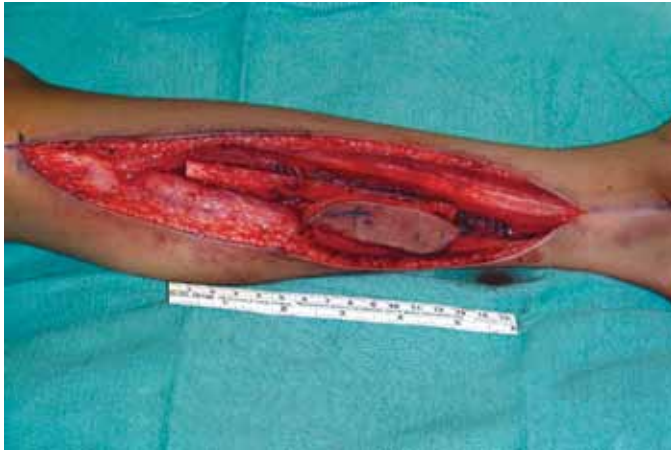bony defect was approximately 7 cm in length with an overlying soft tissue defect of 1-2 cm in length and 5-6 cm in width. Negative tumor margins were confirmed by frozen sections. In a simultaneous procedure, a second team comprising plastic surgeons harvested an osseocutaneous flap from the right fibula with a skin paddle attached to it (Fig. 3). The bone flap was then contoured to the previously fashioned titanium plate and was fixed to the native mandible using titanium screws. Microvascular arterial anastomosis was then achieved between the peroneal artery of the flap and the



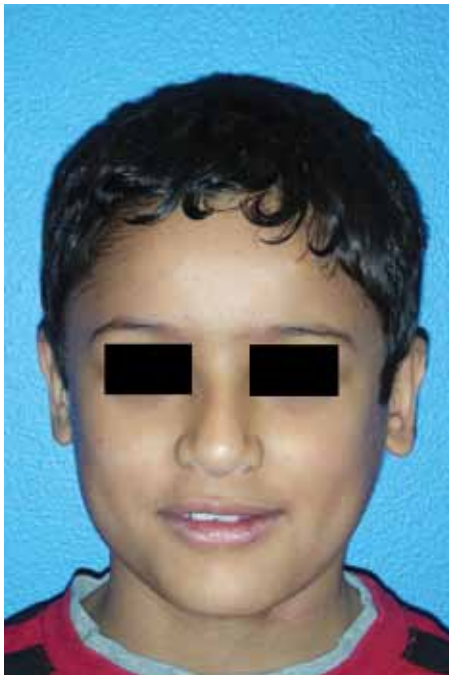**1** Preoperative image of patient. Note contour of native mandible, especially on left side.



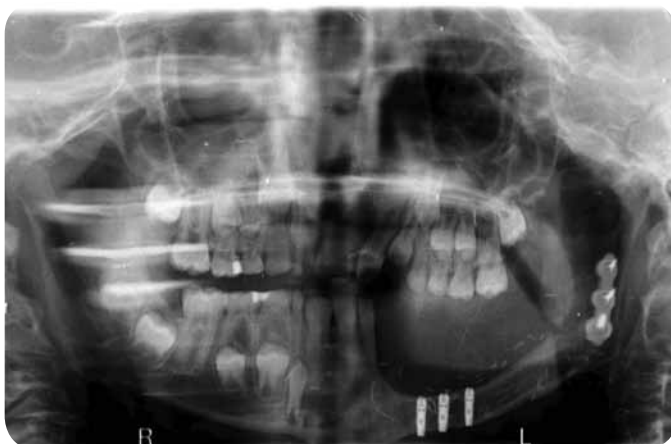**2** Resected mandible with tumor revealing amount of defect needing to be reconstructed.



**3** Fibula bone flap from patient's right leg was harvested along with skin paddle attached to it.



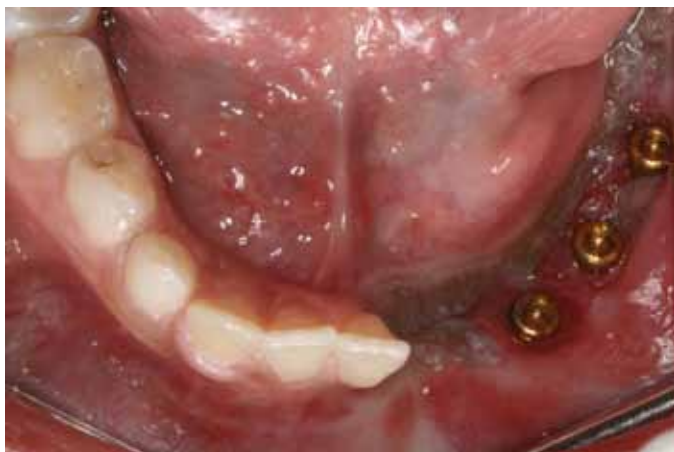**4** Seven months following successful reconstruction of mandible. Note acceptable facial contour on reconstructed (left) side. Compare with Figure 1.



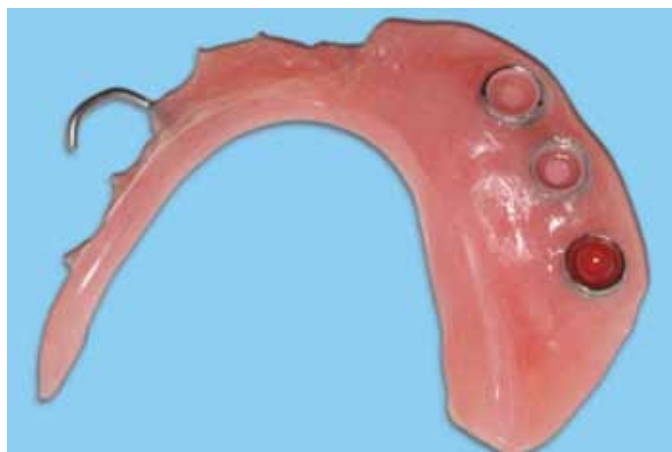**5** Panoramic radiograph showing 3 implants placed in fibula bone upon removal of titanium plate. Note amount of prosthetic material that will be required to contact occlusal plane.

facial artery, and venous anastomosis between the larger of the 2 flap vena comitans and the common facial vein stump.

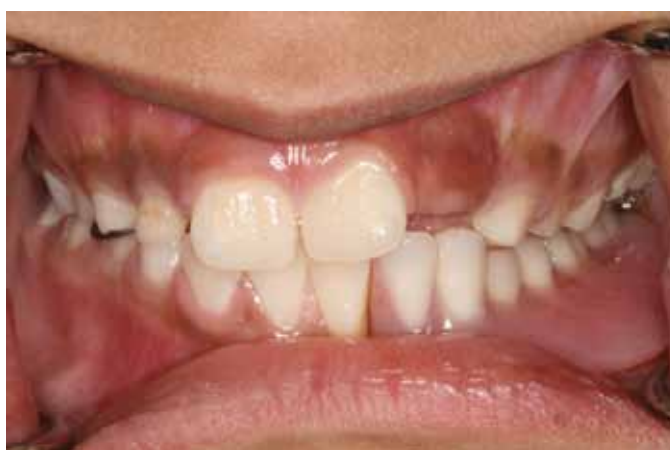During a subsequent follow-up examination, a removable maxillary orthodontic retainer was inserted to prevent supraeruption of the patient's maxillary left posterior teeth. Seven months after the successful reconstruction of the mandible, surgery was performed under general anesthesia for the removal of a portion of the titanium plate and placement of dental implants by the maxillofacial prosthodontist (Fig. 4). Based on the dimensions of the available bone from the fibula graft, 3 implants (OsseoSpeed; Astra Tech, Inc, Waltham, Mass) with dimensions of 3.5 mm x 9 mm were placed. All of the implants engaged both cortices of the fibula and had primary stability at the time of placement. Cover screws (Astra Tech, Inc) were placed on the implants, and the skin flap was closed over the implants (Fig. 5). Four months after implant placement, the implants were uncovered and demonstrated no mobility, bone loss, or clinical signs of any infection. Abutments (Locator; Zest Anchors, Escondido, Calif), 5 mm in cuff height, were torqued to 25 Ncm on all 3 implants. At this time, the 1-cm-thick skin flap over the implants was debulked to facilitate easier access to the abutments and maintenance of the soft tissues. A removable stent made of autopolymerizing resin (Dentsply Repair Material; Dentsply Intl, York, Pa) was immediately fabricated and attached to the Locator abutments to prevent the debulked tissues from growing over the abutments during the healing period. This implant-supported stent extended across the contralateral side and had a wrought wire clasp on the right first primary molar for easier insertion and removal by the patient. The removable stent allowed the patient greater access for brushing around his teeth and abutments. A fluocinonide cream, 0.5 mg/g (Lidex; Medicis Pharmaceuticals Corp, Scottsdale, Ariz), was also prescribed



**6** Soft tissues comprising skin and native mucosa around abutments reveal acceptable tissue health.



**7** Completed mandibular resection prosthesis.



**8** Frontal view of mandibular resection prosthesis in maximum intercuspation. Note buccal extension of prosthesis, which terminates on Locator abutments.

to the patient for topical application to facilitate healing (Fig. 6).

Following 2 weeks of healing of the debulked tissues, a final impression was made using vinyl polysiloxane material (Take 1; Kerr Corp, Orange, Calif), and the definitive cast was poured twice in type IV stone (Denstone; Heraeus Kulzer, South Bend, Ind). A heat-polymerized record base (Lucitone 199 Denture Resin; Dentsply Trubyte, York, Pa), with a wrought wire clasp on the primary right first molar, was fabricated on the first cast incorporating the Locator attachments. The second cast was used to make a maxillomandibular relationship record and mount the casts in a semi-adjustable articulator. Monoplane acrylic resin denture teeth (BlueLine; Ivoclar Vivadent, Amherst, NY) of the appropriate shade were

chosen for simplicity, as the opposing teeth were in the mixed dentition stage. The trial denture prosthesis confirmed the lingualized positions of the prosthetic teeth in relation to the implants; this was because the implants had been placed in a fibula flap that had been contoured to the inferior border of the native mandible to preserve facial esthetics. This is a common complication in fibula flap-reconstructed patients, as the fibula is generally buccal to the occlusal table of the opposing teeth.

After evaluation of the trial denture, the prosthesis was fabricated in heat-polymerized acrylic resin (Lucitone 199 Denture Resin; Dentsply Trubyte). The attachment patrices (Locator; Zest Anchors) were placed in the completed prosthesis and the prosthesis was inserted (Fig.

7). The patient and his parents were instructed in insertion and removal procedures, maintenance, and future remakes of the prosthesis (Fig. 8). The oral hygiene regimen prescribed to the patient included daily flossing and brushing the teeth with a fluoride-containing toothpaste, brushing the prosthesis with soap and water, and cleaning the abutments with a soft cloth soaked in a 0.12% chlorhexidine rinse (Periogard; Colgate-Palmolive, Morristown, NJ). The patient was instructed to constantly wear the prosthesis except when performing oral hygiene procedures. This was recommended to prevent surrounding tissues from becoming hyperplastic over the abutments, as well as to prevent supraeruption of the opposing teeth.

The patient and his parents were informed of potential facial asymme-

try and related occlusal discrepancies in the future due to lack of growth in the reconstructed segment of the mandible. At the 1-year follow-up examination after implant surgery, all 3 implants were stable and the prosthesis was adjusted to accommodate changes in the dentition. The patient and his parents reported satisfaction with the prosthesis. The patient was placed on regular recalls with the oncology team as well as with his pediatric dentist. Additionally, the patient and his parents were instructed to seek consultation from an orthodontist.

## DISCUSSION

The prosthodontic treatment plan chosen for this patient was based on several factors. The mandibular resection prosthesis not only served to maintain esthetics and occlusal relationships but also contributed to the patient's psychological well being. Given the age of the patient, an argument can be made for delay in implant placement in the fibula bone due to the additional surgeries, additional appointments, and increased expenses that were involved. However, the authors believe that a stable mandibular resection prosthesis supported by dental implants can significantly aid in preventing supraeruption of the opposing maxillary dentition and collapse of the growing maxillary arch. This was especially important in this growing patient, as the neuromuscular control was under development and the thickness and flaccidity of the soft tissue flap precluded a good supporting base for a conventional mandibular resection prosthesis. There is a lack of evidence to demonstrate that growth will occur in a reconstructed mandible using fibula bone. Thus, placement of dental implants in the fibula bone would not appear to result in problems such as change in implant positions, as reported in the literature related to native mandibles of growing children.<sup>11-12,22,23</sup>

At the time of implant placement,

3 was the maximum number of implants that could be placed, given the height and contour of the fibula and the limited mouth opening of the young patient. A fourth implant could be placed in the future, if required. This implant would have to be placed in the anterior region, as any additional posterior implants would perhaps encroach on the cheek (Fig. 6). This is a common problem in patients reconstructed with fibula flaps, as the fibula bone is generally contoured using the inferior border of the native mandible as a guide to preserve facial esthetics. Thus, as one proceeds posteriorly, the surgical platform will be placed buccally, due to the natural divergence of the body of the mandible.

As the patient was only 7 years old, it was determined that a removable prosthesis would be the treatment of choice for 2 main reasons. First, it would help facilitate easier modifications and future remakes of the prosthesis to accommodate the continued growth of the right half of the native mandible, growth of the maxilla, development of occlusal vertical dimension, and the patient's transition to permanent dentition. It was for this reason that a removable prosthesis with a cast metal framework was avoided. Secondly, a removable prosthesis could aid in easier monitoring of any local recurrence, which has been reported to be the most common complication of osteosarcoma of the jaw.<sup>5-7</sup>

A potential disadvantage to the chosen removable treatment option is that the patient will have to undergo additional surgical procedures if he desires a fixed prosthesis in the future. An opportunity for a fixed prosthesis might exist, but only if additional implants are placed. However, the authors believe that the existing fibula graft and implants are restricted in height, and any vertical cantilever forces generated on a unilateral, completely implant-supported, fixed prosthesis on this foundation might be detrimental. An alternative option for the patient is to have an addition-

al fibula graft with the double-barrel technique followed by additional implant surgeries for placement of a fixed dental prosthesis.<sup>24</sup> The patient will need to be educated about these additional procedures and their related challenges in the future.

## SUMMARY

This clinical report described the maxillofacial rehabilitation of a 7-year-old boy who underwent a composite resection of a large segment of his left mandible for treatment of osteosarcoma. Simultaneously, a free osseocutaneous fibula flap was used to reconstruct his mandible. This was followed by placement of dental implants and fabrication of an implant-tissue-supported removable mandibular resection prosthesis. The prosthesis aided in providing esthetic, functional, and psychological satisfaction to the patient. The importance of a multidisciplinary approach and treatment planning concerns in a growing child with a reconstructed mandible were discussed. Given the potential for local recurrence of this type of disease and the fact that the patient has a substantial amount of maxillofacial growth remaining, close monitoring from a multidisciplinary team is essential and is in progress.

## REFERENCES

1. Lenhard RE, Osteen RT, Gansler T. Clinical oncology. Atlanta: The American Cancer Society, Inc; 2001. p. 592-96.
2. American Cancer Society. Detailed guide: Osteosarcoma. What are the key statistics about osteosarcoma? [http://www.cancer.org/docroot/CRI/content/CRI\\_2\\_4\\_1X\\_What\\_are\\_the\\_key\\_statistics\\_for\\_osteosarcoma\\_52.asp?sitearea](http://www.cancer.org/docroot/CRI/content/CRI_2_4_1X_What_are_the_key_statistics_for_osteosarcoma_52.asp?sitearea). Accessed on December 27, 2008.
3. Silverman S. Oral cancer. 5<sup>th</sup> ed. Hamilton: BC Decker; 2003. p. 184-6.
4. Gadwal SR, Gannon FH, Fanburg-Smith JC, Becoskie EM, Thompson LD. Primary osteosarcoma of the head and neck in pediatric patients: a clinicopathologic study of 22 cases with a review of the literature. *Cancer* 2001;91:598-605.
5. Bennett JH, Thomas G, Evans AW, Speight PM. Osteosarcoma of the jaws: a 30-year retrospective review. *Oral Surg Oral Med Oral Pathol Oral Radiol Endod* 2000;90:323-32.

6. van Es RJ, Keus RB, van der Waal I, Koole R, Vermey A. Osteosarcoma of the jaw bones. Long-term follow up of 48 cases. *Int J Oral Maxillofac Surg* 1997;26:191-7.

7. August M, Magennis P, Dewitt D. Osteogenic sarcoma of the jaws: factors influencing prognosis. *Int J Oral Maxillofac Surg* 1997;26:198-204.

8. Laskar S, Basu A, Muckaden MA, D'Cruz A, Pai S, Jambhekar N, et al. Osteosarcoma of the head and neck region: lessons learned from a single-institution experience of 50 patients. *Head Neck* 2008;30:1020-6.

9. Fernandes R, Nikitakis NG, Pazoki A, Ord RA. Osteogenic sarcoma of the jaw: a 10-year experience. *J Oral Maxillofac Surg* 2007;65:1286-91.

10. Bjork A. Variations in the growth pattern of the human mandible: longitudinal radiographic study by the implant method. *J Dent Res* 1963;42:400-11.

11. Cronin RJ Jr, Oesterle LJ, Ranly DM. Mandibular implants and the growing patient. *Int J Oral Maxillofac Implants* 1994;9:55-62.

12. Cronin RJ Jr, Oesterle LJ. Implant use in growing patients. Treatment planning concerns. *Dent Clin North Am* 1998;42:1-34.

13. Hidalgo DA. Fibula free flap: a new method of mandible reconstruction. *Plast Reconstr Surg* 1989;84:71-9.

14. Lee H, Ercoli C, Fantuzzo JJ, Girotto JA, Coniglio JU, Palermo M. Oral rehabilitation of a 12-year old patient diagnosed with a central giant cell granuloma using a fibula graft and an implant-supported prosthesis: a clinical report. *J Prosthet Dent* 2008;99:257-62.

15. Ionomou TG, Zuker RM, Phillips JH. Mandibular reconstruction in children using the vascularized fibula. *J Reconstr Microsurg* 1999;15:83-90.

16. Gbara A, Darwich K, Li L, Schmelzle R, Blake F. Long-term results of jaw reconstruction with microsurgical fibula grafts and dental implants. *J Oral Maxillofac Surg* 2007;65:1005-9.

17. Chiapasco M, Biglioli F, Autelitano L, Romeo E, Brusati R. Clinical outcome of dental implants placed in fibula-free flaps used for the reconstruction of maxillo-mandibular defects following ablation for tumors or osteoradionecrosis. *Clin Oral Implants Res* 2006;17:220-8.

18. Klesper B, Wahn J, Koebeke J. Comparisons of bone volumes and densities relating to osseointegrated implants in microvascularly reconstructed mandibles: a study of cadaveric radius and fibula bones. *J Craniomaxillofac Surg* 2000;28:110-5.

19. Teoh KH, Huryn JM, Patel S, Halpern J, Tunick S, Wong HB, et al. Implant prosthodontic rehabilitation of fibula free-flap reconstructed mandibles: a Memorial Sloan-Kettering Cancer Center review of prognostic factors and implant outcomes. *Int J Oral Maxillofac Implants* 2005;20:738-46.

20. Gürlek A, Miller MJ, Jacob RF, Lively JA, Schusterman MA. Functional results of dental restoration with osseointegrated implants after mandible reconstruction. *Plast Reconstr Surg* 1998;101:650-5.

21. Kramer FJ, Dempf R, Bremer B. Efficacy of dental implants placed into fibula-free flaps for orofacial reconstruction. *Clin Oral Implants Res* 2005;16:80-8.

22. Sharma AB, Vargervik K. Using implants for the growing child. *J Calif Dent Assoc* 2006;34:719-24.

23. Kearns G, Sharma A, Perrott D, Schmidt B, Kaban L, Vargervik K. Placement of endosseous implants in children and adolescents with hereditary ectodermal dysplasia. *Oral Surg Oral Med Oral Pathol Oral Radiol Endod* 1999;88:5-10.

24. Jones NF, Swartz WM, Mears DC, Jupiter JB, Grossman A. The "double barrel" free vascularized fibular bone graft. *Plast Reconstr Surg* 1988;81:378-85.

**Corresponding author:**

Dr Avinash S. Bidra  
University of Texas Health Science Center at San Antonio  
7703 Floyd Curl Drive, MSC 7912  
San Antonio, TX 78229-3900  
Fax: 210-567-6376  
E-mail: avinashbidra@yahoo.com

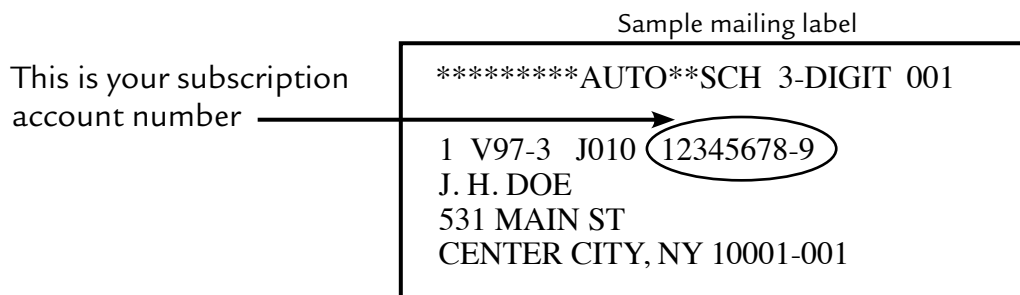
**Acknowledgements**

The authors thank Dr F. Christopher Holsinger, head and neck surgeon, and Dr Peter Anderson, pediatric oncologist, M.D. Anderson Cancer Center, Houston, Tex, for their involvement with the care of this patient.

Copyright © 2009 by the Editorial Council for *The Journal of Prosthetic Dentistry*.

Access to *The Journal of Prosthetic Dentistry Online* is reserved for print subscribers!

Full-text access to *The Journal of Prosthetic Dentistry Online* is available for all print subscribers. To activate your individual online subscription, please visit *The Journal of Prosthetic Dentistry Online*. Point your browser to <http://www.journals.elsevierhealth.com/periodicals/ympr/home>, follow the prompts to activate **online access here**, and follow the instructions. To activate your account, you will need your subscriber account number, which you can find on your mailing label (*note*: the number of digits in your subscriber account number varies from 6 to 10). See the example below in which the subscriber account number has been circled.



Personal subscriptions to *The Journal of Prosthetic Dentistry Online* are for individual use only and may not be transferred. Use of *The Journal of Prosthetic Dentistry Online* is subject to agreement to the terms and conditions as indicated online.