

Facial Moulage Fabrication Using a Two-Stage Poly(vinyl siloxane) Impression

Abdullah S. Alsiyabi, BDS, MS;¹ and Glenn E. Minsley, DMD²

Traditional techniques for the fabrication of a facial moulage have relied on materials with various shortcomings. This article describes a two-stage Poly(vinyl siloxane) impression technique that avoids some of these shortcomings and provides a predictable and accurate facial moulage.

J Prosthodont 2006;15:195-197. Copyright © 2006 by The American College of Prosthodontists.

INDEX WORDS: facial moulage, poly(vinyl siloxane) (PVS) impression, elastomeric impression materials, irreversible hydrocolloid-plaster impression

A FACIAL PROsthESIS must have intimate adaptation to the adjacent skin. The fabrication of a well-adapted facial prosthesis relies on obtaining an accurate moulage and subsequent master cast. The conventional technique for making a moulage of facial defects uses irreversible hydrocolloid supported by a fast-setting plaster matrix; however, the inherent properties of the impression material, such as imbibition or syneresis, overall weight of the moulage, and limited working time, can often result in distortion and dimensional inaccuracy of the moulage and the subsequent definitive prosthesis.

Various techniques have been reported in the literature to provide improvement in the accuracy of facial moulages.¹⁻³ Over the years, a wide variety of dental materials have been used for making moulages, including irreversible hydrocolloid, polysulfide, Poly(vinyl siloxane) (PVS), and polyether.⁴⁻⁸ Other materials have been used to

provide a rigid backing for the impression, including impression plaster, acrylic-tray resin, and a prefabricated custom impression tray.^{4,7-9}

This article describes a facial moulage technique using two viscosities of PVS impression material (Extrude[®], Kerr Cooperation, Romulus, MI).

Two-Stage PVS Impression Technique

1. The area for the moulage is initially defined (Fig 1).
2. Facial hair within the defined area is protected by a light application of petroleum jelly.
3. The patient is seated in the physiological rest position, halfway between the upright and supine positions, to minimize the effects of gravity on the peri-defect tissue. Also, it is difficult, if not impossible, to contain the flow of the impression material with the patient seated fully upright.
4. The area to be impressed is cleaned with diluted hydrogen peroxide solution, using sterile cotton rolls and gauze.
5. In the case of a nasal defect, the patient's nostrils are blocked using lubricated sterile gauze, and the patient is instructed to breathe through the mouth for the duration of the impression procedure (Fig 2).
6. A single sheet of baseplate wax (regular TruWax Baseplate Wax, Denstply International Inc., York, PA) is adapted between the intra-oral bite plane and the external bow of a Fox guide plane (Zahn Dental Co, Inc., Waterbury, NY). The wax is contoured and adapted

¹Head of Prosthodontics Department, Military Dental Services, Royal Army of Oman, Sultanate of Oman, formerly Graduate Prosthodontics Resident, UNC School of Dentistry, Chapel Hill, NC.

²Associate Professor, Department of Prosthodontics, UNC School of Dentistry, Chapel Hill, NC.

Accepted February 14, 2005.

Correspondence to: Dr. Abdullah S. Alsiyabi, BDS, MS, Military Dental Center, Royal Army of Oman, P.O. Box 1097, Postal Code 132, Alkoudh, Wilayat Al-seeb, Sultanate of Oman. E-mail: nibras97@omantel.net.om

Presented at the Table Clinic Session in the 51st Annual Meeting of the American Academy of Maxillofacial Prosthetics in Scottsdale, AZ, November 2003.

Copyright © 2006 by The American College of Prosthodontists

1059-941X/06

doi: 10.1111/j.1532-849X.2006.00100.x

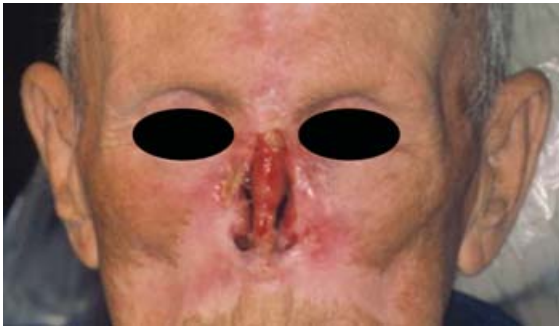

Figure 1. Nasal defect.

to the adjacent skin of the face, while the guide plane is positioned against the maxillary teeth and upper lip to provide a barrier preventing any impression material from flowing into the patient's mouth during the impression procedure.

7. A thin wash of low-viscosity PVS impression material is syringed into the defect and the surrounding tissue.
8. While the material is still soft, broken tongue depressor sections are gently embedded over the external surface of the impression material and arranged in various directions. Cotton rolls are shredded into a thin mesh of cotton fibers to make small tufts, which are then embedded over other areas of the material to provide retention for the high-viscosity PVS impression material. The low-viscosity PVS impression material is allowed to reach its final set, then a thin coat of PVS tray adhesive (Caulk Tray Adhesive, Dentsply Caulk, Dentsply International Inc., Milford, DE) is

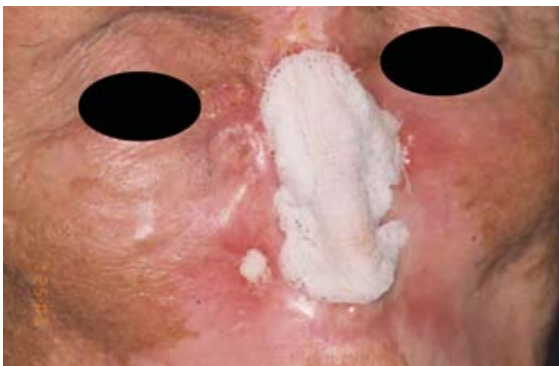

Figure 2. Defect blocked with sterile gauze.

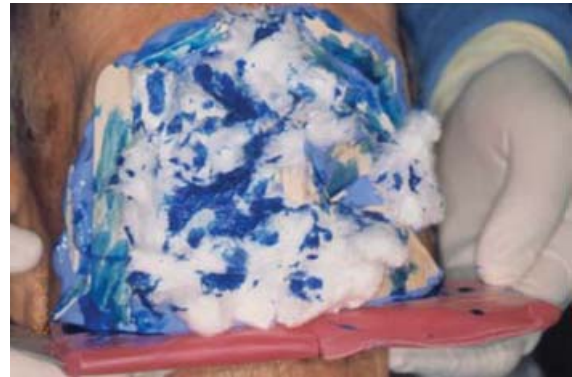


Figure 3. Low-viscosity PVS impression.

applied over the cotton mesh and allowed to dry (Fig 3).

9. A layer of high-viscosity PVS impression material is syringed over the low-viscosity PVS impression material. Excessive thickness can cause unnecessary distortion. Broken tongue depressor sections are then embedded in this high-viscosity layer while the material is still fluid. They are again arranged in various directions throughout the external surface for reinforcement and support (Fig 4). This lattice of tongue blades arranged in various directions on the low- and high-viscosity PVS impression materials forms a rigid assembly that holds the impression intact during the procedure and prevents its flexure in all directions when poured.
10. The high-viscosity PVS is left undisturbed to set completely.



Figure 4. High-viscosity PVS impression.

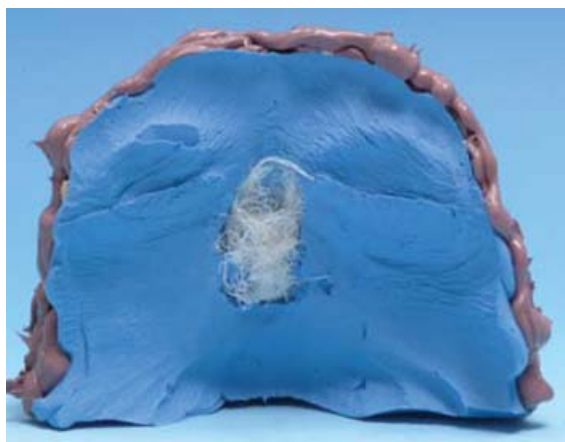


Figure 5. Intaglio surface of elastomeric impression.

11. The impression is slowly and gently removed from the defect (Fig 5).
12. The impression is then poured in type IV dental stone (Silky Rock, WhipMix Corp., Louisville, KY) to generate the master cast (Fig 6).

Discussion

This technique for the fabrication of a facial moulage eliminates the need for a custom tray and thus an additional impression of the patient, which reduces laboratory and clinical time. This impression procedure can be used when making an impression for any facial defect.

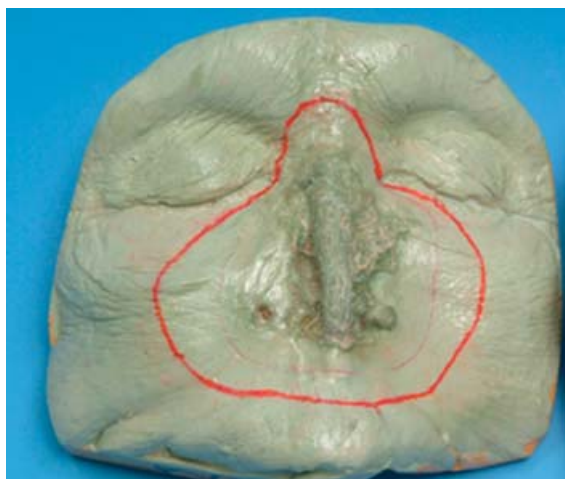


Figure 6. Master cast.

PVS impression material is indicated for the technique because of its dimensional stability, resistance to deformation, ease of flow, and high tear strength on setting, in comparison to irreversible hydrocolloid material.^{10,11} These physical qualities allow material retrieval from the defect without tearing or distortion. The use of low- and high-viscosity PVS impression materials reinforced with tongue blades provides the necessary rigidity for the moulage, while greatly reducing the impression material's weight on the soft tissue. The relatively high cost of the PVS impression material appears to be one of the few disadvantages of the two-stage PVS impression technique.

Summary

A two-stage technique for the fabrication of a facial moulage is presented. This technique efficiently employs the use of two viscosities of PVS material to generate a highly detailed and accurate master cast.

References

1. Walter WS, Gelfand G, Gans BJ: A new technique for making a moulage. *J Oral Surg* 1975;33:220-222
2. Ma T, Taylor TD, Johnson M: A boxing technique for making moulages of facial defects. *J Prosthet Dent* 1990;63:564-566
3. Coleman AJ, Schweiger JW, Urquiola J, et al: A two-stage impression technique for custom facial prostheses. *J Prosthet Dent* 1995;73:370-372
4. Thomas KF: *Prosthetic Rehabilitation*. London, Quintessence, 1994, pp 176-181
5. Branemark PI, Tolman DE: *Osseointegration in Craniofacial Reconstruction*. Chicago, IL, Quintessence, 1998, pp 214-216
6. Beumer J, Curtis TA, Marunick MT: *Maxillofacial Rehabilitation: Prosthodontic and Surgical Considerations*. St Louis, MO, Ishiyaku EuroAmerica, 1996, p 401
7. Wolfaardt JF, Coss P, Levesque R: Craniofacial osseointegration: Technique for bar and acrylic resin substructure construction for auricular prostheses. *J Prosthet Dent* 1996;76:603-607
8. Wolfaardt JF, Wilkes GH, Anderson JD: Craniofacial Osseointegration: Prosthodontic Treatment. In: Taylor TD, ed. *Clinical Maxillofacial Prosthetics*. Chicago, IL, Quintessence, 2000, pp 286-291
9. Kubon TM, Anderson JD: An implant-retained auricular impression technique to minimize soft tissue distortion. *J Prosthet Dent* 2003;89:97-101
10. O'Brien WJ: *Dental Materials and Their Selection* (ed 3). Chicago, IL, Quintessence, 2002
11. Phillips RW: *Skinner's Science of Dental Materials* (ed 9). Philadelphia, PA, Saunders, 1991, pp 135-156