

# Auricular Reconstruction: Indications for Autogenous and Prosthetic Techniques

Charles H. Thorne, M.D., Lawrence E. Brecht, D.D.S., James P. Bradley, M.D., Jamie P. Levine, M.D., Paul Hammerschlag, M.D., and Michael T. Longaker, M.D.

New York, N.Y.

**Learning Objectives:** After studying this article, the participant should be able to: 1. Describe the alternatives for auricular reconstruction. 2. Discuss the pros and cons of autogenous reconstruction of total or subtotal auricular defects. 3. Enumerate the indications for prosthetic reconstruction of total or subtotal auricular defects. 4. Understand the complexity of and the expertise required for prosthetic reconstruction of auricular defects.

The indications for autogenous auricular reconstruction versus prosthetic reconstruction with osseointegrated implant-retained prostheses were outlined in *Plastic and Reconstructive Surgery* in 1994 by Wilkes et al. of Canada, but because of the relatively recent Food and Drug Administration approval (1995) of extraoral osseointegrated implants, these indications had not been examined by a surgical unit in the United States. The purpose of this article is to present an evolving algorithm based on an experience with 98 patients who underwent auricular reconstruction over a 10-year period. From this experience, the authors conclude that autogenous reconstruction is the procedure of choice in the majority of pediatric patients with microtia. Prosthetic reconstruction of the auricle is considered in such pediatric patients with congenital deformities for the following three relative indications: (1) failed autogenous reconstruction, (2) severe soft-tissue/skeletal hypoplasia, and/or (3) a low or unfavorable hairline. A fourth, and in our opinion the ideal, indication for prosthetic ear reconstruction is the acquired total or subtotal auricular defect, most often traumatic or ablative in origin, which is usually encountered in adults. Although prosthetic reconstruction requires surgical techniques that are less demanding than autogenous reconstruction, construction of the prosthesis is a time-consuming task requiring experience and expertise. Although autogenous reconstruction presents a technical challenge to the surgeon, it is the prosthetic reconstruction that requires lifelong attention and may be associated with late complications. This article reports the first American series of auricular reconstruction containing both autogenous and prosthetic methods by a single surgical team. (*Plast. Reconstr. Surg.* 107: 1241, 2001.)

Alternatives for auricular reconstruction include autogenous reconstruction using a rib

cartilage framework, prosthetic reconstruction with osseointegrated implants for retention of the prosthesis, or use of an alloplastic framework (e.g., porous polyethylene) rather than a cartilage framework. The latter alternative is not addressed in this article. The complication rate and eventual extrusion rate associated with Silastic frameworks make its use undesirable.<sup>1-3</sup> Recent reports of polyethylene frameworks are encouraging but await long-term evaluation.<sup>4</sup>

The choice between the two remaining techniques, autogenous reconstruction and prosthetic reconstruction, depends more on the surgeon's training and tradition than on an analysis of which procedure is preferable in a given clinical situation. For example, most children with microtia in the United States are treated with autogenous techniques. In contrast, the same deformities in Sweden are more commonly treated with prosthetics.<sup>5,6</sup> The indications for prosthetic reconstruction have been outlined by Wilkes et al.<sup>7</sup> of Canada, but no American series combining autogenous and prosthetic techniques has been published.

In the hands of an experienced plastic surgeon who performs the procedure on a regular basis, autogenous techniques yield consistent results in the majority of pediatric patients with microtia. Several large series have been reported that demonstrate excellent results.<sup>8-10</sup>

Most surgeons, however, do not have the experience with this rare condition (approximately 1:4000 births) to duplicate the results reported in the large series. In addition, autogenous ear reconstruction has the disadvantage that a sub-optimal result might be uncorrectable.

Although prosthetic reconstruction of the auricle has an established track record outside the United States, it did not become a viable alternative in the United States until January of 1995, when the Food and Drug Administration approved the extraoral use of Brånemark osseointegrated implants (Nobel Biocare USA Inc., Yorba Linda, Calif.). Before that date, ear prostheses were not well tolerated because of the inconvenience and ineffectiveness of chemical adhesives. Osseointegration, the direct structural connection between living bone and a load-carrying implant, has reduced the problems of prosthesis retention and inconvenience.<sup>5,6,11</sup>

We postulate that each of these two methods has a role in auricular reconstruction and that neither technique is appropriate for every clinical situation. Therefore, the purpose of this article is to present an evolving algorithm for auricular reconstruction based on the senior authors' (C.H.T. and L.E.B.) experience with patients who have undergone auricular reconstruction.

#### MATERIALS AND METHODS

Between 1989 and 1998, a total of 145 patients were evaluated in a multidisciplinary fashion with regard to plastic surgery, prosthodontics, and otolaryngology. The senior authors, C.H.T. (plastic surgery) and L.E.B. (prosthodontics) performed reconstructive procedures on 98 patients during that time period. A total of 84 patients underwent autogenous reconstruction using the technique described by Brent.<sup>8</sup> All patients in this group were children with microtia (Fig. 1).

Prosthetic reconstruction was performed in 14 patients (18 ears) after the Food and Drug Administration approval of Brånemark implants (Nobel Biocare) in 1995. The prosthetic group contained patients in both the pediatric (six patients, 10 ears) and adult (eight patients, eight ears) age groups; it included patients with congenital, posttraumatic, and postablative deformities (eight, three, and three patients, respectively). The age and diagnosis of each patient in the prosthetic group are shown in Table I.

In the prosthetic group, both the plastic surgeon and prosthodontist were present in the operating room at the time of fixture placement. In the initial patients in the series, the transcutaneous abutments were placed at a second stage approximately 3 months after im-

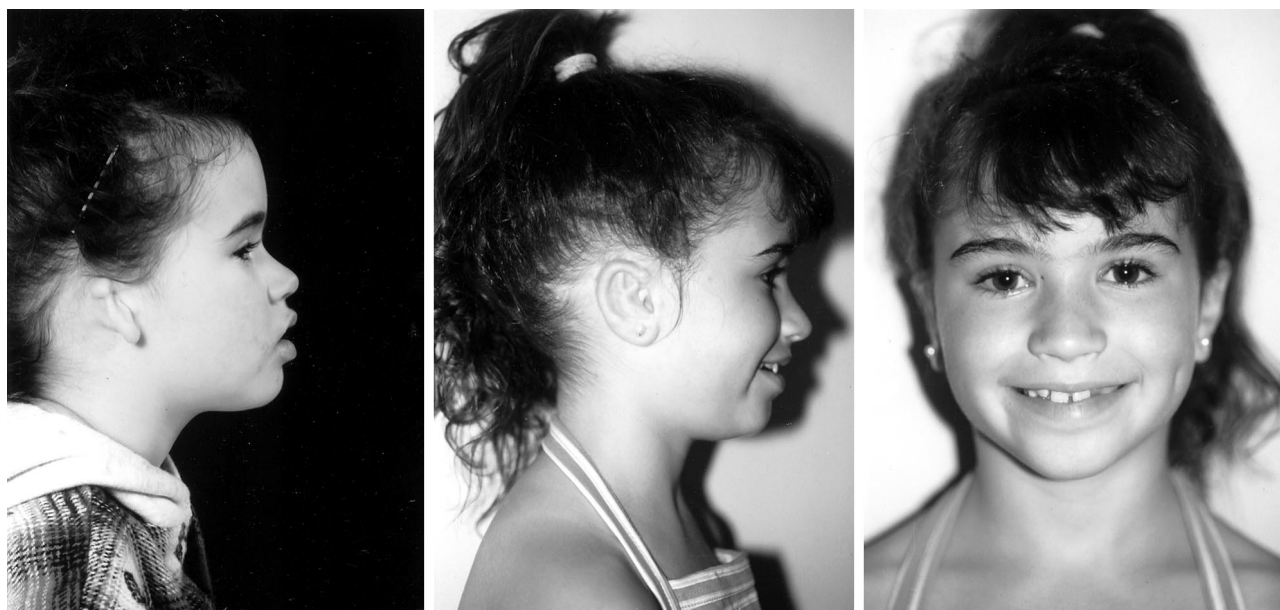

FIG. 1. Autogenous reconstruction. The patient underwent a staged reconstruction, as described by Brent.<sup>8</sup> (*Left*) Preoperative appearance; (*center* and *right*) postoperative result. On frontal view, the position of the auricle is symmetrical, as judged by the position of the earrings. This patient's microtic vestige contained a tragus-like structure, making that stage of the reconstruction more favorable than average.

TABLE I  
Implant-Retained Prosthetic Reconstruction

Patient	Age	Unilateral or Bilateral	Diagnosis
1	4	Unilateral	Congenital
2	8	Bilateral	Congenital
3	9	Bilateral	Congenital
4	14	Unilateral	Congenital
5	14	Bilateral	Congenital
6	15	Bilateral	Congenital
7	25	Unilateral	Congenital
8	28	Unilateral	Congenital
9	34	Unilateral	Posttraumatic
10	49	Unilateral	Postablative
11	53	Unilateral	Posttraumatic
12	53	Unilateral	Posttraumatic
13	61	Unilateral	Postablative
14	63	Unilateral	Postablative

plant placement. In the more recent cases, the fixtures and abutments were placed concomitantly in a single stage.

As experience with the prosthetic technique was obtained and literature from other countries using the technique was acquired, the authors developed an algorithm for distinguishing between candidates for autogenous reconstruction and prosthetic reconstruction.

## RESULTS

Despite increased experience with the prosthetic technique, after using it in the pediatric age group the authors have not altered their opinion that the majority of children with congenital anomalies are best treated with autogenous techniques. Nevertheless, there is a subset of pediatric patients with congenital anomalies in whom it may be reasonable to consider prosthetic ear replacement. On the basis of our experience, we arrived empirically at the following relative indications for prosthetic reconstruction (the first three relative indications involve congenital cases; the fourth involves acquired deformities):

### 1. Failed Autogenous Reconstruction

Patients with a failed autogenous reconstruction may represent the ideal indication in the pediatric age group for an implant-retained prosthesis (Fig. 2). The scarring associated with previous surgical attempts may preclude further autogenous reconstruction or require transfer of a temporoparietal flap for framework coverage. In some patients, the temporoparietal fascia may have been used, necessitating either microvascular transfer of the contralateral temporoparietal fascia or a prosthetic reconstruction. In dark-skinned patients

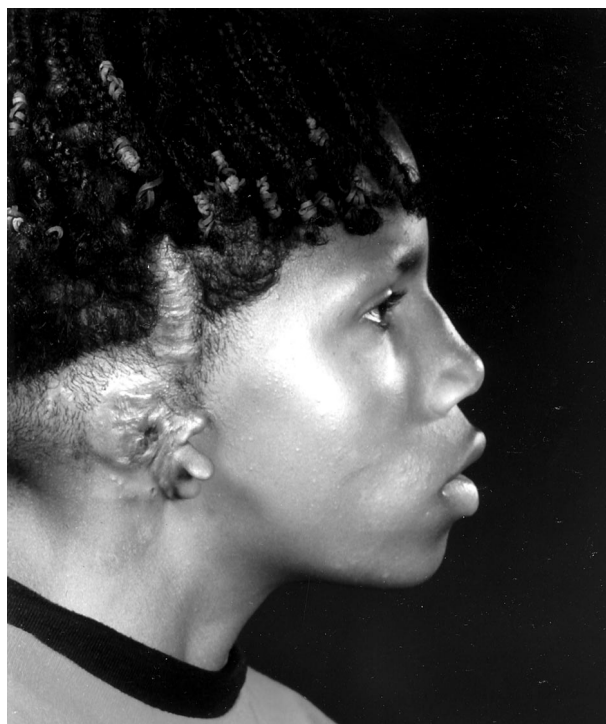


FIG. 2. A failed autogenous reconstruction. The patient had undergone attempts at auricular reconstruction elsewhere. In addition to the scarring associated with the failed auricular reconstruction, the patient also has hypertrophic scarring in the scalp, most likely related to temporoparietal flap harvest. Further attempts at autogenous reconstruction would be difficult, making prosthetic reconstruction a reasonable option.

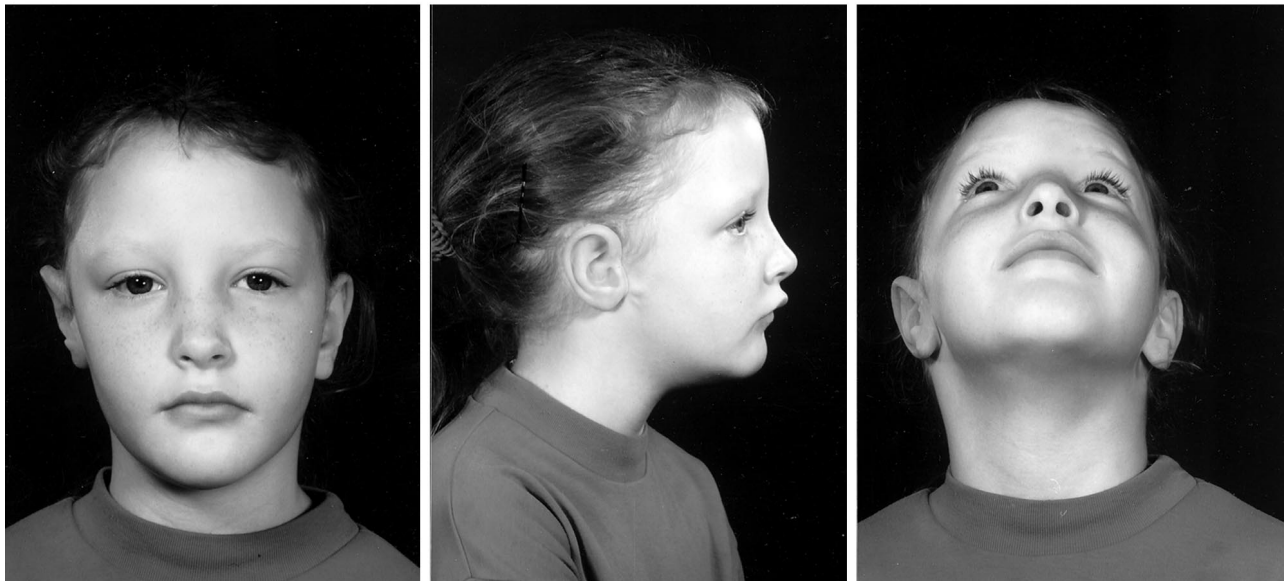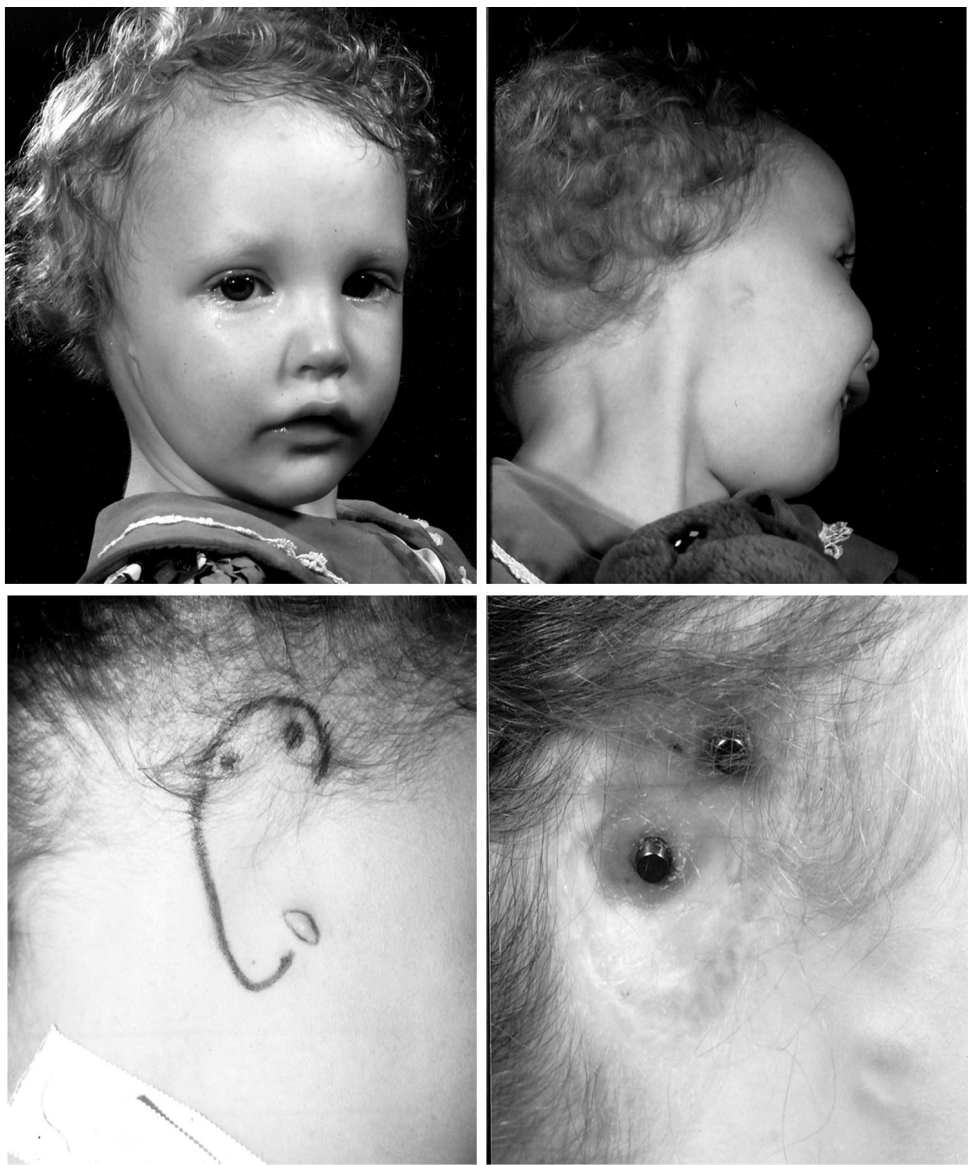prone to hypertrophic scarring, scalp incisions associated with temporoparietal flap harvest may present a significant deterrent to that technique, and prosthetic reconstruction may be a better alternative than a second attempt at autogenous reconstruction. Moreover, patients and their families may be hesitant to proceed with a second attempt at autogenous reconstruction after an initial failure.

### 2. Severe Soft-Tissue and/or Skeletal Hypoplasia

Patients with hemifacial microsomia who demonstrate the extreme manifestations of soft-tissue deficiency and/or skeletal hypoplasia represent the most challenging clinical scenario, and no perfect solution currently exists.

Some patients with hemifacial microsomia present with tight skin, absence of a superior skin remnant, and a small or almost absent lobule (Fig. 3). The cutaneous deficit limits the result that can be obtained with autogenous reconstruction. For example, there may be inadequate skin to drape into the interstices of a framework. In some patients, the cutaneous





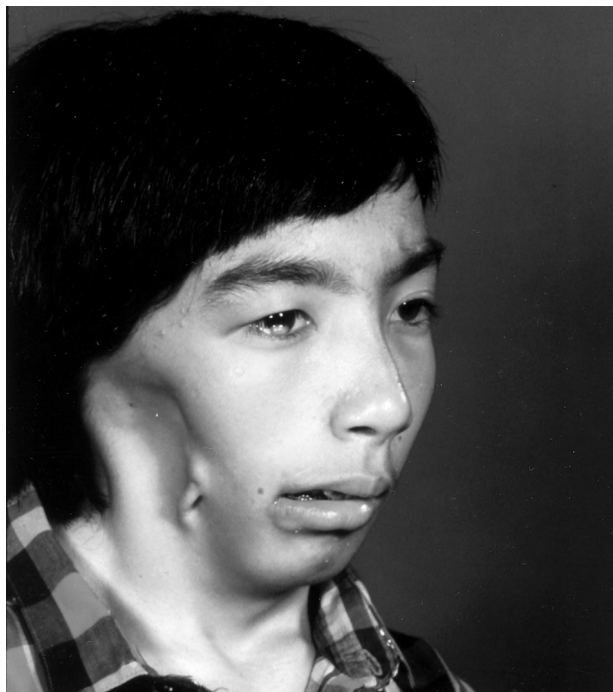


FIG. 4. Combination of soft-tissue and skeletal hypoplasia. This patient demonstrates the extreme manifestation of hemifacial microsomia with severe soft-tissue and hard-tissue hypoplasia. Although autogenous techniques can be used to construct an auricle, the temporal concavity limits the result. In addition, the patient will require numerous surgical procedures, including orthognathic surgery and microvascular surgery. Prosthetic reconstruction of the auricle is simpler and less invasive, and it may appeal to the patient and his or her family for those reasons. Nevertheless, the ideal procedure may be to disguise the temporal deficiency with the microvascular soft-tissue augmentation and then to perform autogenous ear reconstruction.

deficit is such that the placement of a standard framework will result in ischemia of the overlying tight skin. In those patients it is necessary to reduce the projection of the framework to ensure viability of the overlying skin, which further limits the ultimate result.

Skeletal hypoplasia also limits the result that can be obtained by autogenous reconstruction. Some patients present with a temporal concavity resulting from hypoplasia of the mandibular ramus and the temporal bone, such that any reconstructed auricle will not project ade-

quately (Fig. 4). Despite mandibular reconstruction, the contour of the temporal region remains uncorrected.

Patients with the more severe manifestations of hemifacial microsomia often present with the limitations of soft-tissue hypoplasia and skeletal hypoplasia concomitantly. Not only is autogenous reconstruction limited, but the degree of facial asymmetry makes auricular reconstruction less of a priority. The more severe the asymmetry, the greater the relative importance of the orthognathic surgery and the microvascular soft-tissue augmentation, the results of which (being closer to the facial midline) are more noticeable on frontal view. In these patients it may not be possible to produce an aesthetically adequate auricle using autogenous techniques. These patients face numerous reconstructive procedures for the skeletal and soft-tissue hypoplasia and may be better treated with an implant-retained prosthesis and alterations in hairstyle.

The authors' treatment algorithm continues to evolve in these difficult cases. Currently under investigation is a change in the order of reconstructive procedures; the soft-tissue augmentation is currently performed before auricular reconstruction, completely correcting the temporal concavity, and then auricular reconstruction is considered on this reconstructed platform.

### 3. Low or Unfavorable Hairline

Management of the hairline is always an issue in the patient with a congenital ear deformity. If the hairline is slightly low, a compromise can be struck by constructing an auricle that is smaller than the normal side. In this manner, the superior aspect of the framework is not covered with hair. From an aesthetic point of view, it is more important to have the caudal aspect of the auricle (lobule) in a symmetric position relative to the contralateral side than to have symmetry of the superior aspects of the auricle, which are more easily

FIG. 3. Severe soft-tissue hypoplasia. (*Above*) Preoperative appearance demonstrating almost complete absence of any auricular vestige. In addition, the hairline is slightly low. (*Center, left*) Preoperative plan indicating the desired position of the eventual prosthesis and the anticipated location of the fixtures within the auricular outline. The location of the fixtures may be modified intraoperatively, depending on the thickness and quality of the bone. (*Center, right*) Appearance after the excision of hair-bearing scalp, placement of fixtures, split-thickness skin graft, and placement of the transcutaneous abutments. Note the soft-tissue irritation. The patient had been wearing the prosthesis for several months. Inflammation is quite common in children who do not care for the area as meticulously as an adult patient. This degree of erythema responds well to using aggressive hygiene around the abutments and decreasing the number of hours per day that the patient wears the prosthesis. (*Below*) Postoperative result. Note the difficulty in disguising the anterior margin of the prosthesis in the absence of a tragus.



camouflaged by hairstyle. A small amount of hair over the superior aspect of the auricular reconstruction can be treated in a number of ways: electrolysis, laser ablation, and excision/skin graft. In addition, various techniques have been described to alter the hairline before initiating autogenous reconstruction.<sup>12,13</sup> In patients who present with an extremely low hairline, however, in whom the majority of the framework would be covered with hair-bearing skin, prosthetic reconstruction represents an

alternative (Figs. 5 and 6). Although these patients can undergo autogenous reconstruction with temporoparietal flap coverage of the framework, that technique may not be desirable in all patients.

As laser technology improves, it may become possible to permanently ablate the hair in the precise location for auricular reconstruction, but at the present time, the hair removal is not permanent and repeated treatments are required. In addition, the hair-bearing scalp con-

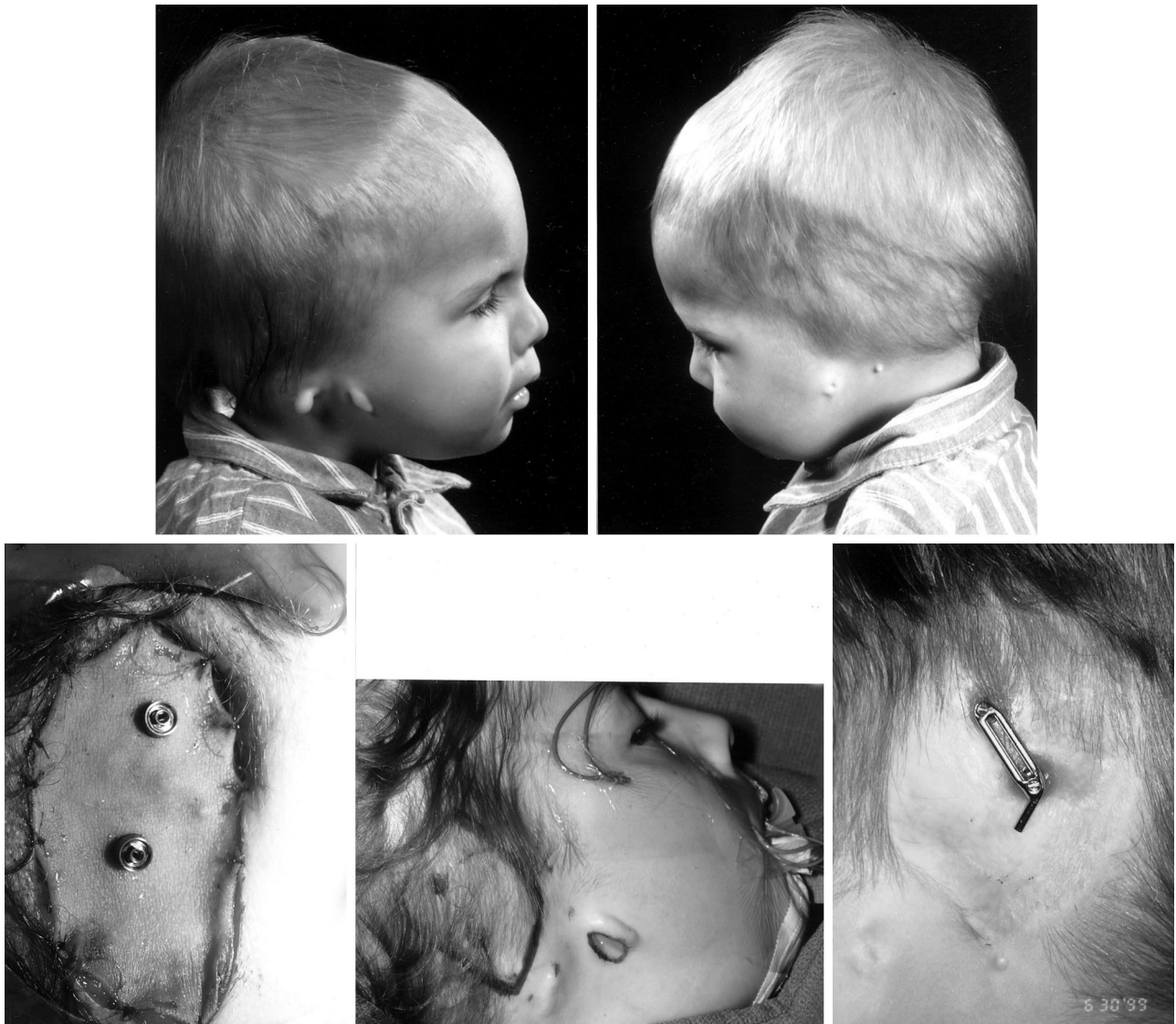


FIG. 5. A bilateral low or unfavorable hairline. (*Above*) Preoperative appearance. The hairline is extremely low, extending almost to the angle of the mandible. (*Below, center*) Intraoperative photograph indicating the area where the hair-bearing scalp will be removed and the temporal skull will be covered with a split-thickness skin graft. The ideal location of the fixtures has been marked within the outline of the eventual auricle. The patient is shown with facial nerve monitors in place, an important safety measure when complex external auditory canal remnants are excised. Hidden behind the auricular vestige in the center of the photograph, outlined by the marking pen, is a malpositioned external auditory meatus. The patient had a long, serpiginous external auditory canal remnant, which opened to the skin in that location. The tract was completely excised. (*Below, left*) Intraoperative photograph demonstrating skin-graft and transcutaneous abutments on one side. (*Below, right*) Mild inflammation around the abutments is evident.

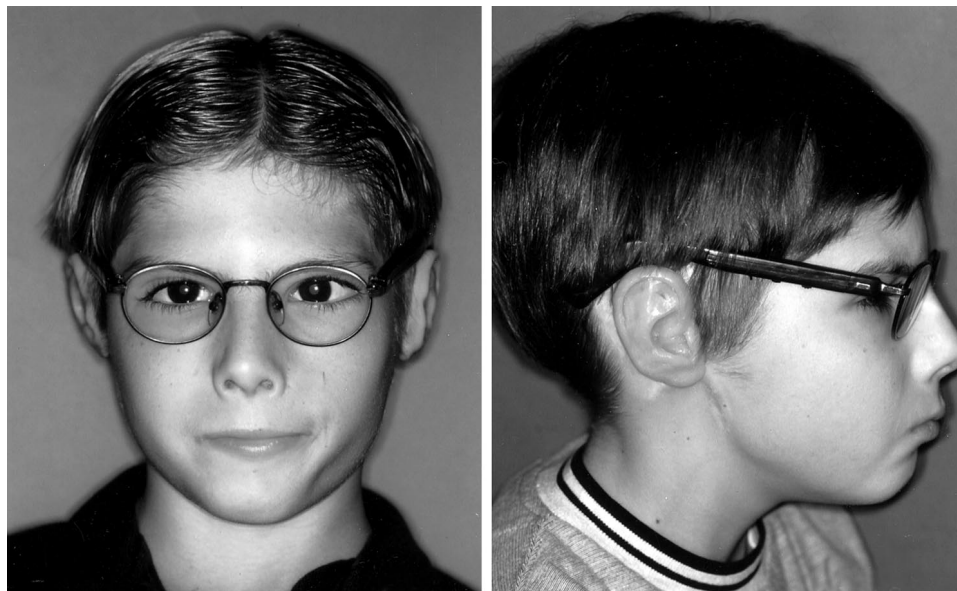


FIG. 6. Postoperative result. On frontal view the bilateral prostheses are symmetrical, resulting in the eyeglasses appearing to be level. On oblique view, the hairstyle that attempts to disguise the anterior margin of the prosthesis is demonstrated.

sists of thicker skin than that which would normally cover an ear framework, which further blunts the ultimate aesthetic result, even if the hair has been removed.

#### 4. Posttraumatic or Postablative Auricular Defects

Patients with posttraumatic or postablative auricular defects are more often adults, and their defects differ from those of children with congenital deformities in several ways. First, the skin loss and scarring resulting from trauma or previous surgery may make standard autogenous reconstruction difficult. Second, the tragus is frequently preserved in the trauma/ablative patient, making the aesthetics of prosthetic reconstruction much more favorable (Fig. 7). The presence of a tragus allows the anterior border of the prosthesis to be hidden, a major aesthetic benefit. In general, patients with congenital deformities do not have a tragus, and the anterior margin of the prosthesis, no matter how elegantly constructed, is always visible. The presence of a tragus is important enough for the aesthetics of the result that it may be reasonable in some patients to reconstruct the tragus before prosthetic reconstruction of the remaining auricle. The authors, however, have no experience with this modification. Third, adults tend to have more heterogeneous skin pigmentation and heterogeneous skin texture, which makes the prosthesis much less visible than in a young

child with smooth, homogeneous skin color and texture. Finally, adults are less inclined to undergo staged reconstruction, and prosthetic reconstruction may be, or may be perceived as, a simpler alternative. In addition, some patients who have undergone resection of the auricle for oncologic indications may have been treated with radiotherapy, which further complicates, or precludes, an autogenous reconstruction.

#### DISCUSSION

Autogenous ear reconstruction using a rib cartilage framework was first described by Gillies,<sup>14</sup> later developed by Tanzer,<sup>15-17</sup> and further refined by Brent.<sup>8</sup> As a result of these reports, particularly the large series by Brent, autogenous reconstruction using cartilage frameworks has become the standard technique for ear reconstruction in the United States. Nagata, of Japan,<sup>10</sup> and Firmin, of France<sup>9</sup> also presented large series of patients who demonstrated superb results with autogenous reconstruction. The standard results obtained by these experts are difficult to match because the deformity is rare. As in other areas in plastic surgery, but perhaps even more so, the first attempt at reconstruction is of paramount importance because a suboptimal result may be uncorrectable.

Because consistently good results with autogenous reconstruction have proved elusive in the hands of many surgeons around the world,



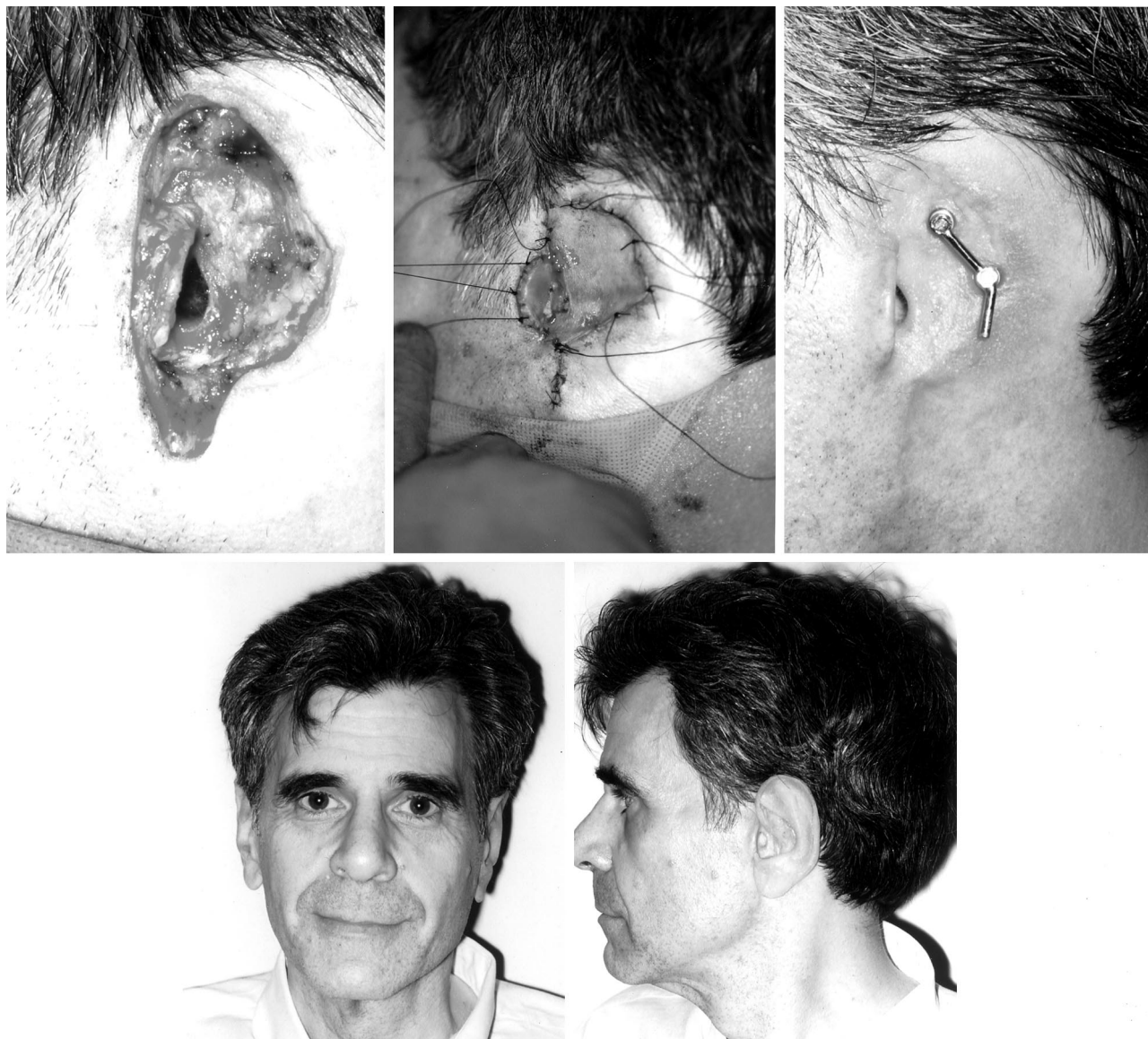


FIG. 7. Postablative indication for prosthetic reconstruction. (*Above, left*) Intraoperative photograph demonstrating the defect after resection of the auricle for malignant melanoma with multiple satellite lesions. (*Above, center*) Intraoperative photograph following posterior cheek advancement to cover the lateral surface of the tragal cartilage, and skin-graft coverage of the exposed mastoid bone and the medial surface of the tragus. (*Above, right*) Appearance of the soft tissue demonstrating the absence of inflammation around the abutments because of the patient's compliance with treatment and use of adequate hygiene. (*Below*) Postoperative appearance of the prosthesis. The prosthetic auricle is on the patient's left side.

other techniques for auricular reconstruction have been evaluated. To date, replacing the cartilage framework with an alloplastic framework has not proved to be effective. Cronin introduced the Silastic framework, and the technique was complicated by a high rate of framework extrusion.<sup>1-3</sup> Many of these complications occurred late, often years after the original procedure. Reinisch used a framework consisting of polyethylene (Medpor, Porex Surgical Inc., Atlanta, Ga.) in more than 100 patients, with promising early results. His ini-

tial cases demonstrated a 44 percent complication rate.<sup>4</sup> Changes in the operative technique, consisting of complete coverage of the alloplastic framework with a temporoparietal flap, have almost eliminated the complication rate in the short run. Although the technique is encouraging, it may be a decade or more before the long-term outcome of the alloplastic framework is determined.

Prosthetic reconstruction of the auricle has been available for centuries, but ineffective, messy, and inconvenient adhesives have de-



tracted from its practicality. In addition, there is tremendous variability in the aesthetic quality of prostheses and, given the problems with retention, any prosthesis must be aesthetically excellent for the patient to tolerate its use.

As documented by reports of Brånemark osseointegrated titanium implants (Nobel Biocare) for the retention of dental prostheses, these fixtures have been used in other parts of the craniofacial skeleton for the retention of prosthetic devices. Tjellstrom reported on the technique for the retention of auricular prostheses.<sup>5,6</sup> Although the intraoral uses of titanium implants have been available for some time, it has only been since 1995 that the technique has been approved for extraoral use in the United States.

Although Wilkes et al. elegantly described the indications for prosthetic ear reconstruction, no American series combining autogenous reconstruction and prosthetic reconstruction has yet been published.<sup>7</sup>

The advantages and disadvantages of the two techniques (autogenous reconstruction and implant-retained prosthetic reconstruction) are enumerated below:

#### 1. Finite Nature of Autogenous Reconstruction

Once an autogenous reconstruction is completed, the patient requires no further treatment. In contrast, prosthetic reconstruction requires replacement of the prosthesis every 2 to 5 years for the life of the patient. In addition, the skin/implant interface is prone to irritation, and there may be periods of time when the patient cannot wear the prosthesis. In our experience, irritation at the skin/implant interface is common in children (Fig. 3, *center, right* and Fig. 5, *below, right*), who may not administer the meticulous hygiene necessary around the transcutaneous abutments.

#### 2. Psychological

Once completed, autogenous ear reconstruction in the pediatric patient is incorporated immediately into the patient's self-image, allowing most patients to put the deformity behind them and move forward with life's other priorities. By contrast, the prosthetic auricle must be put in place every morning and removed every night for the life of the patient, serving as a daily reminder to the patient of his or her deformity. When the prosthesis is not in place, the metal retention suprastruc-

ture is exposed, giving the patient a "bionic" appearance.

#### 3. Resistance to Trauma and Infection

Once incorporated, the cartilage framework of an autogenous reconstruction is largely resistant to trauma and infection. Lacerations that expose the incorporated cartilage heal uneventfully, and any infection in the region tends to respond to antibiotics. In contrast, although quite sturdy, the abutment/fixture complex can be dislodged and even lost if subjected to sufficient trauma. For this reason, some contact sports may not be advisable, or even possible, for children with implant-retained prostheses.

#### 4. Aesthetics

An experienced and talented anaplastologist can produce a prosthetic auricle of superb aesthetic quality and with a degree of detail and projection that cannot be matched by an autogenous reconstruction. Nevertheless, no prosthesis has the texture, temperature, and quality of normal skin. In addition, the prosthesis can approximate but not duplicate precisely the color match of an autogenous reconstruction. Finally, as mentioned above in the discussion of posttraumatic and postablative deficits, the absence of a tragus in most pediatric patients with a congenital deformity is a limiting factor in the aesthetics of a prosthetic reconstruction. (As Firmin points out, it is also a limiting factor in the final aesthetics of a Brent-type reconstruction.<sup>9</sup>) The anterior margin of the prosthesis, which cannot be disguised behind the tragus, will always be visible, no matter how expert the anaplastologist.

#### 5. Cost

Despite the large up-front costs associated with autogenous reconstruction the lifetime requirements for care and prosthetic replacement (every 5 years, minimum) especially in a pediatric patient with a long life-expectancy, make the costs associated with prosthetic reconstruction greater than the cost of autogenous reconstruction. In addition to financial cost, the need for lifelong medical surveillance further adds to the burden of the prosthetic alternative.

#### 6. Lifeboat

Finally, an autogenous reconstruction does not "burn bridges" for future prosthetic recon-

struction, but prosthetic reconstruction does preclude future autogenous reconstruction. Prosthetic reconstruction requires excision of all ear remnants and of the skin and soft tissue in the region, making a subsequent autogenous reconstruction almost impossible. In fact, we have found that the ideal soft-tissue environment for the implant-retained prosthesis is a skin graft directly on bone. On the other hand, if a misadventure occurs with autogenous reconstruction, prosthetic reconstruction is still an option.

Because of the overwhelming advantages of autogenous reconstruction, it remains the technique of choice for children requiring auricular reconstruction. The fact that the technique requires experience does not change its desirability.

Nevertheless, prosthetic reconstruction is a valuable technique. The primary indication is the acquired deformity, generally a result of trauma or ablative surgery. Relative indications exist in the congenital cases, when the aesthetics of a prosthesis are sufficient to overcome the disadvantages described above. The four indications described represent situations in which the results from autogenous reconstruction are limited, making prosthetic reconstruction a reasonable alternative.

The neophyte is cautioned against the belief that prosthetic reconstruction is easier or less time-consuming than autogenous reconstruction. Relatively "easy surgery" does not mean an "easy reconstruction." Although the plastic surgeon's role in a prosthetic reconstruction may be confined to fixture placement and preparation of the local soft tissue, construction of the retention mechanism and the prosthesis is extremely time-consuming, requiring numerous visits over the course of weeks. For this reason, it is easy for the plastic surgeon to underestimate the requirements for prosthetic reconstruction.

In addition, as with autogenous reconstruction, the ultimate aesthetics of the result depend on the skill of the person creating the actual prosthesis. Even if the fixtures are well incorporated in bone and the soft tissue has healed around the abutments, the reconstruction is not a success unless the prosthesis is of excellent quality.

The authors have not had difficulty with future integration despite the thin bone in pediatric patients. Although it is ideal to insert the fixtures in bone measuring at least 3 mm in

thickness, the bone is frequently 1 to 2 mm thick in young patients. The holes are carefully drilled to avoid injury to underlying dura. Even if the bone is thin, 3-mm fixtures are placed, indenting the dura as they are inserted. If the drilling encounters a mastoid air cell, the fixtures are placed in the same manner, regardless of the bone thickness. To date, no fixtures have been lost. In patients in whom there is concern about bone thickness, it may be reasonable to delay the placement of transcutaneous abutments until a second surgical stage.

Skin expansion has been suggested as an ancillary technique for patients with tight skin or an inadequate amount of skin. In this series, the authors did not find it useful.

One final factor that may discourage prosthetic reconstruction in the United States is low reimbursement from insurance companies. It is difficult to find a talented, experienced prosthodontist or anaplastologist to perform time-consuming prosthesis construction without a financial incentive. Other health-care systems around the world (e.g., Canada and Sweden) may lessen the above bias toward autogenous reconstruction, but the vagaries of health-care economics do not change the underlying reality that a good result from autogenous reconstruction is more desirable than any prosthetic result.

In the seminal article on this subject by Wilkes et al., the indications used by their team for prosthetic reconstruction are listed: cancer resection, radiotherapy, absent lower half of the ear, severely compromised tissue, patient preference, failed autogenous reconstruction, potential craniofacial anomaly, and poor operative risk.<sup>7</sup> Although we chose to list fewer indications for the prosthetic alternative, our conclusions are essentially identical.

#### SUMMARY

As the technology of tissue engineering improves and experience is gained with Medpor (Porex Surgical) and other materials, it is possible that there may be alternatives to autogenous reconstruction and prosthetic reconstruction of the auricle. Nevertheless, in the opinion of the authors, for now the latter two techniques represent the optimal choices for most patients requiring total or subtotal auricular reconstruction. In our opinion, it is unlikely that the role of prosthetic reconstruction will increase. More probably, continued advances in techniques supporting autogenous recon-

struction (e.g., laser ablation of hair, improved techniques for skeletal reconstruction, and tissue-engineered cartilage frameworks) will extend the indications for autogenous reconstruction to those patients in the four categories above who are not ideal candidates at present. The primary indication for prosthetic reconstruction will remain the acquired total or subtotal auricular defect, generally in the adult patient.

Charles H. Thorne, M.D.  
812 Park Avenue  
New York, N.Y. 10021  
ct322@aol.com

## REFERENCES

1. Cronin, T. D. Use of a Silastic frame for total and subtotal reconstruction of the external ear: Preliminary report. *Plast. Reconstr. Surg.* 37: 399, 1966.
2. Cronin, T. D. Reconstruction of the ear in one stage with Silastic framework and fascial flap. Presented at the Annual Meeting of the California Plastic Surgical Society, Monterey, Calif., March 9, 1979.
3. Cronin, T. D., and Ascough, B. M. Silastic ear construction. *Clin. Plast. Surg.* 5: 367, 1978.
4. Reinisch, J. Microtia reconstruction using a polyethylene implant: An eight year surgical experience. Presented at the 78th Annual Meeting of the American Association of Plastic Surgeons, Colorado Springs, Colo., May 5, 1999.
5. Tjellstrom, A. Osseointegrated implants for replacement of absent or defective ears. *Clin. Plast. Surg.* 17: 355, 1990.
6. Tjellstrom, A., Lindstrom, J., Nylen, O., et al. The bone-anchored auricular epithesis. *Laryngoscope* 91: 811, 1981.
7. Wilkes, G. H., Wolfaardt, J. F., and Dent, M. Osseointegrated alloplastic versus autogenous ear reconstruction: Criteria for treatment selection. *Plast. Reconstr. Surg.* 93: 967, 1994.
8. Brent, B. Auricular repair with autogenous rib cartilage grafts: Two decades of experience with 600 cases. *Plast. Reconstr. Surg.* 90: 355, 1992.
9. Firmin, F. Ear reconstruction in cases of typical microtia: Personal experience based on 352 microtic ear corrections. *Scand. J. Plast. Reconstr. Surg. Hand Surg.* 32: 35, 1998.
10. Nagata, S. A new method of total reconstruction of the auricle for microtia. *Plast. Reconstr. Surg.* 92: 187, 1993.
11. Brånemark, P. I., Hansson, B. O., Adell, R., et al. Osseointegrated implants in the treatment of the edentulous jaw: Experience from a 10-year period. *Scand. J. Plast. Reconstr. Surg. Suppl.* 16:1, 1977.
12. Letterman, G. S., and Harding, R. L. The management of the hairline in ear reconstruction. *Plast. Reconstr. Surg.* 18: 199, 1956.
13. Yotsuyanagi, T., Yokoi, K., Nihei, U., et al. Management of the hairline using a local flap in total reconstruction for microtia. *Plast. Reconstr. Surg.* 104: 41, 1999.
14. Gillies, H. *Plastic Surgery of the Face*. London: Frowde, Hodder and Stoughton, 1920. P. 381.
15. Tanzer, R. C. Total reconstruction of the external ear. *Plast. Reconstr. Surg.* 23: 1, 1959.
16. Tanzer, R. C. Total reconstruction of the auricle: The evolution of a plan of treatment. *Plast. Reconstr. Surg.* 47: 523, 1971.
17. Tanzer, R. C. Microtia. *Clin. Plast. Surg.* 5: 317, 1978.

**Self-Assessment Examination follows on  
page 1252.**



# Self-Assessment Examination

## Auricular Reconstruction: Indications for Autogenous and Prosthetic Techniques

*by Charles H. Thorne, M.D., Lawrence E. Brecht, D.D.S., James P. Bradley, M.D., Jamie P. Levine, M.D., Paul Hammerschlag, M.D., and Michael T. Longaker, M.D.*

1. THE IDEAL INDICATION FOR PROSTHETIC RECONSTRUCTION OF AN AURICULAR DEFECT IS
  - A) A child with microtia
  - B) A child with complications from autogenous reconstruction of microtia
  - C) An adult with a helical rim defect related to resection of a basal cell carcinoma
  - D) An elderly adult who has undergone removal of an ear for a cutaneous malignancy
2. WHICH OF THE FOLLOWING ARE FAVORABLE SOFT-TISSUE CHARACTERISTICS FOR PROSTHETIC RECONSTRUCTION OF THE AURICLE? (MORE THAN ONE MAY BE CORRECT.)
  - A) Loose, unscarred, thick soft tissue around the transcutaneous abutments
  - B) Thin, immobile soft tissue or scar adherent to the underlying skull
  - C) Presence of a tragus
  - D) Absence of a tragus
3. WHICH OF THE FOLLOWING REPRESENT RELATIVE INDICATIONS FOR PROSTHETIC RECONSTRUCTION IN CHILDREN WITH MICROTIA?
  - A) Failed autogenous reconstruction
  - B) Severe soft-tissue/skeletal hypoplasia
  - C) Low or unfavorable hairline
  - D) All of the above
4. PROSTHETIC RECONSTRUCTION OF AURICULAR DEFECTS IS SUBSTANTIALLY EASIER AND REQUIRES LESS TIME AND SKILL THAN AUTOGENOUS RECONSTRUCTION.
  - A) True
  - B) False
5. PROSTHETIC RECONSTRUCTION OF MICROTIA IN A CHILD IS CHEAPER IN THE LONG RUN THAN AUTOGENOUS RECONSTRUCTION.
  - A) True
  - B) False
6. IMPLANT-RETAINED PROSTHETIC RECONSTRUCTION OF THE AURICLE HAS BEEN AVAILABLE IN THE UNITED STATES ONLY SINCE 1995.
  - A) True
  - B) False
7. THE DAILY HYGIENE AND MAINTENANCE REQUIRED OF AN IMPLANT-RETAINED PROSTHETIC RECONSTRUCTION OF THE AURICLE IS MINOR AND IS EASY FOR CHILDREN.
  - A) True
  - B) False
8. AN AUTOGENOUS RECONSTRUCTION DOES NOT "BURN THE BRIDGE" FOR LATER PROSTHETIC RECONSTRUCTION, BUT AN IMPLANT-RETAINED PROSTHETIC RECONSTRUCTION DOES "BURN THE BRIDGE" FOR LATER AUTOGENOUS RECONSTRUCTION.
  - A) True
  - B) False

To complete the examination for CME credit, turn to page 1329 for instructions and the response form.